



Bioscientia Medicina: Journal of Biomedicine & Translational Research

Journal Homepage: www.bioscmed.com

Treatment of Infantile Hemangioma

Indri Widya Sari^{1*}, Fitriani¹, Soenarto Kartowigno¹

¹Department of Dermatology and Venereology, Faculty of Medicine Universitas Sriwijaya, Palembang, Indonesia

ARTICLE INFO

Keywords:

Hemangioma
Clinical Manifestation
Treatment

Corresponding author:

Indri Widya Sari

E-mail address:

indri.widya88@gmail.com

All authors have reviewed and approved the final version of the manuscript.

<https://doi.org/10.32539/bsm.v5i1.184>

ABSTRACT

Infantile hemangioma represents the most common benign tumour arising in infancy. The natural history of infantile hemangioma is characterized by a proliferative phase during the first few months of life, followed by slower involution over the years. Evolution of infantile hemangioma has four stages, contain nascent, proliferation, involution, and involuted. Most infantile hemangioma do not require active treatment and involute without leaving significant residual. However, some infantile hemangioma is problematic due to complications such as ulceration, interference with a vital function, or potential disfigurement. The management approach for IH contains active non-intervention and active intervention. The decision of treatment is based on many factors, including size and location, psychosocial implication, risks and benefits of the proposed therapy. Early recognition of infantile hemangioma is essential for optimal management and preventing complication.

1. Introduction

Infantile hemangiomas (IHs) is a benign vascular tumour marked by rapid proliferative phase with subsequent slower involution. They are more common in a girl, ratio 2 to 3:1, affect up to 30% of premature infants, especially those weighing less than 2500 g.^{1,2} Prevalence of IH in Dr Mohammad Hoesin Palembang Hospital from January 2016 – September 2020 are 71 patients.

The pathogenesis of IH, despite intensive study, has not been completely elucidated. Intrinsic and extrinsic factors are also thought to contribute to their development. Intrinsic factors include the influence of angiogenic and vasculogenic factors within the IH. External factors include tissue hypoxia and developmental field disturbances.³

Diagnose of IH from anamnesis and clinical examination. The supportive analysis is needed for atypical lesion, with complications and potentially life-

threatening.²

IH management uses two approaches, active non-intervention and active intervention. Most IH only requires a dynamic non-intervention approach because it can regress spontaneously, no need to be treated.² In 10-15% of cases IH requires early intervention or a dynamic intervention approach, in potentially life-threatening lesions, large lesions or lesions that cause functional disorders.⁴ Options for active interventional therapy include topical therapy, systemic therapy, laser treatment, and surgery.² Treatment of IH is influenced by various factors, including size and location, functional aspects, psychosocial aspects, risks and benefits of therapy.⁴

Etiopathogenesis

The pathogenesis of IH remains unclear. There are two factors considered influencing the development of

IH. Intrinsic factors include angiogenic and vasculogenic. Extrinsic factors include tissue hypoxia and developmental field disturbances. Several theories explain the process of IH, endothelial progenitor cell (EPCs) theory, imbalance of angiogenic and antiangiogenic factors, hemangioma stem cell (HemeSC), and tissue hypoxia.³⁻⁵

The EPC theory holds that IHs develop from clonal expansion of circulating EPCs, resulting in vasculogenesis, or de novo formation of new blood vessels. This theory is supported by studies showing increased numbers of circulating EPCs in blood samples from children with IH.³

The second theory about the imbalance of angiogenic and antiangiogenic factors. An increase in the level of vascular endothelial growth factor (VEGF), essential growth factor of fibroblast (bFGF), and matrix metalloproteinases (MMPs) 2 and 9. In the regression phase, the levels of these factors decrease, whereas those antiangiogenic factors, including tissue inhibitors of metalloproteinases (TIMP), increase.^{3,5}

Third theory about HemeSC. Hemangioma stem cell produces vascular endothelial growth factor-A (VEGF-A), which activates vasculogenesis by binding to VEGF-receptor (VEGFR-1) and stimulates the differentiation of HemeSCs to endothelial cells. VEGFR-2 also appears to play a role in angiogenesis and vasculogenesis. One of the essential activators of vascular endothelial growth factor-2 production in HemeSCs is nuclear factor κ -light-chain enhancer of activated B cells (NF- κ B). This transcription factor regulates genes involved with inflammation, cell proliferation, and cell survival.⁴

Tissue hypoxia also appears to be an inducer of angiogenesis and vasculogenesis. Hypoxia leads to the activation of hypoxia-inducible factor (HIF-alpha) in HemeSCs, which in turn increases the production and activity of GLUT-1 and VEGF-A. In vitro studies have indicated that hypoxia and estrogen synergistically enhance hemangioma proliferation.⁴

Finally, a new study suggests that the mammalian target of rapamycin (mTOR) may also play a role in stem cell proliferation. mTOR is a protein kinase that regulates cell growth, proliferation, motility, and

survival.⁴

Classification and clinical manifestation

The classification of the International Society for the Study of Vascular Anomalies (ISSVA) divides vascular anomalies into tumours (including infantile haemangiomas and congenital haemangiomas) and malformations. Infantile haemangiomas can be classified morphologically as different types: superficial, deep, mixed (shallow and deep), reticular, abortive or minimal growth. These can exist in different patterns: focal, multifocal, segmental, and indeterminate.⁶ Extracutaneous IHs involve segmental facial lesions with or without PHACE syndrome. Hepatic hemangioma is often associated with the segmental type of IH.²

The growth pattern of IH divided into four proposed stages: nascent, proliferative, involution, and involuted.^{2,7} The nascent stage is the newborn stage before the emergence of lesions, which typically lasts 0–3 months. During the next 6–10 months, proliferation occurs in two phases: an early proliferative phase which brings rapid growth in the first few months of life during which lesions attain most of their size, followed by a late proliferative phase with less rapid growth. In general, 80% of IH achieve their maximum size by five months. As compared to superficial or localized lesions, deep or segmental lesions appear to have slightly prolonged proliferative phases extending slightly beyond six months; however, most lesions still cease growth by nine months of age. The proliferative stage is followed by a plateau or stabilization phase of variable duration. Involution is typically heralded by a change in colour from bright red to grey or purple, as well as a softening texture and flattening or diminution in size—approximately half of IH involute by four years of age and three quarters by age seven.^{2,7} Involved stage is complete resolution. This stage can occur in 50% of patients. Generally, IH lesions change to normal skin. Telangiectasis, atrophy, residual fibrofatty, or scar can occur as sequelae of IH.²

Supportive examination

Most IHs are diagnosed based on their clinical features and supportive examination. The supportive investigation is laboratory, radiology, and histopathology. Hypothyroidism is a rare complication in IH patients with diffuse infantile hepatic hemangioma and PHACE syndrome. Patients with hepatic hemangioma are evaluated for thyroid function, including tests for T3, T4, and TSH.²

Ultrasonography (USG), Computed Tomography Scan (CT-Scan), and Magnetic Resonance Imaging (MRI) are incredibly helpful for confirming the diagnosis and extent of deep IHs that lack superficial changes. MRI or Magnetic Resonance Angiography (MRA) can also be used to determine the presence of hemangiomas within internal organs and to detect other structural anomalies, including CNS malformations and arterial abnormalities. MRI with contrast is the most useful imaging technique for helping to define the extent and tissue characteristics of vascular anomalies, and the use of difference can help to differentiate a hemangioma from other tumours.^{2,6,8} If MRI does not confirm the diagnosis of hemangioma or there are concerns regarding a possible malignancy, histologic examination of the tumour is recommended.

The histopathologic features of IH correlate with the stage of hemangioma development. Biopsy specimens obtained from superficial and deep lesions show the same features. Well-defined non-encapsulated masses composed of proliferating plump endothelial cells and pericytes characterize proliferating hemangiomas. Late proliferating stage, lobules of endothelial masses separated by fibrous septae become more prominent (figure 1). An increased number of mast cells is often present within proliferating hemangiomas, and some studies have found even higher numbers of mast cells during early involution.⁸

The involution phase is marked by flattening of the endothelium and reduced numbers of mitotic figures. Eventually, the vessels decrease in number and lose their tightly packed appearance, with fibrous and fatty tissue separating the vessels within and between lobules. The feeding and draining vessels within the

septae may persist.⁸

Immunohistochemical analysis is useful for confirming the diagnosis of IH (**Figure 2**). As noted above, GLUT1 expression is usually restricted to vessels with blood-tissue barrier functions, such as the brain and placenta. A high level of GLUT1 immunoreactivity is present in the endothelial within IHs of all phases. GLUT1 staining is absent in other types of vascular tumours and vascular malformations. Also, other placenta-associated vascular proteins, including FcγRII, merosin, and Lewis Y antigen, are present in IHs but absent in vascular malformations and pyogenic granulomas.⁸

Diagnosis and differential diagnosis

Infantile hemangioma and vascular malformations are distinguished by history and physical examination, also supportive assessment. Superficial and mixed types of infantile hemangioma are diagnosed based on clinical features.^{6,8} Supportive analysis based on clinical symptoms of IH at each phase. MRI and MRA examinations are currently recommended tests for assessing IH.² Yang et al. compared MRI and CT-scan to diagnose hemangiomas and venous malformations in 55 patients. The results showed MRI has higher sensitivity and specificity than CT-scan. MRI examination has a sensitivity of 84% and specificity 86.7%, while a CT scan has a sensitivity of 76% and specificity of 67%.⁹

Hemangioma precursors and early proliferating lesions may sometimes be misdiagnosed as capillary malformations or telangiectasias. Pyogenic granulomas (PGs) occur commonly in children and may mimic a superficial hemangioma; however, PGs usually arise after the first few months of life and are pedunculated.⁸

Other vascular lesions of infancy that may be in the differential diagnosis of superficial hemangioma include tufted angioma, multifocal lymphoendotheliomatosis with thrombocytopenia, infantile hemangiopericytoma, spindle cell hemangioma, verrucous venous malformation, and eccrine angiomatous hamartoma. Other vascular anomalies that may be considered in the differential

diagnosis of a deep hemangioma include a venous, lymphatic, or combined venous-lymphatic malformation, as well as a congenital hemangioma or kaposiform hemangioendothelioma, Kasabach-Merritt Phenomenon (KMP).⁸

Rhabdomyosarcoma, neuroblastoma, primitive neuroectodermal tumour, lymphoblastic lymphoma, and dermatofibrosarcoma protuberans are other neoplasms that may have a vascular appearance like IH.⁸

Management of infantile hemangioma

The IH management algorithm can be seen in figure 3.¹⁰ Two approaches are used in IH management: active non-intervention and active intervention. Treatment will depend on the location, morphology and stage of evolution, impact on function, risk of disfigurement and comorbidities.⁶

Active Non Intervention

Active non-intervention is appropriate if lesions have a small size, no impairment of function, no ulceration and it is considered that spontaneous regression will produce an excellent outcome (Figure 4).⁸

In the early stages, parents are often very concerned about aesthetic issues. They require a detailed explanation of the natural history of infantile haemangioma, supported with serial photography illustrating examples from the time of maximum proliferation until complete resolution.⁸

During the proliferation phase, observation is carried out every month or twice a month, while in the involution, phase it is carried out annually or twice a year.³

Active Intervention

Active intervention is recommended for IHs with a greater risk of developing local or systemic complications. Active interventions include topical therapy, systemic therapy, laser, and surgery.^{6,8}

The significant goals of management include: preventing or reversing life or function threatening

complications; treating ulcerations; preventing permanent disfigurement; minimizing psychosocial distress to patients and their families; and avoiding overly aggressive, potentially scarring procedures for lesions that have a strong probability of involuting without significant residua.⁸

Topical Therapies

β-blockers

Topical application of timolol maleate, a non-selective β-blocker, can be productive for the treatment of IHs (Figure 5), especially small superficial lesions that are < 1 mm in initial thickness. Timolol is available in several ophthalmic formulation, including 0,5% solution and 0,5% gel-forming solution, with one drop (0,25 mg) twice daily.^{6,8} Chan et al. found this dosing of timolol 0.5% GFS to be an effective and safe therapy for small (<2,5 cm), thin, nonulcerated cutaneous IHs in infants 5–24 weeks of age, with benefit seen after 8–16 weeks of treatment. Danarti et al. reported 278 superficial IH patients divided into three therapy groups. The patient was treated topically with 0.5% timolol maleate gel, 0.5% timolol maleate solution, and ultrapotent corticosteroid then observed for six months. Timolol maleate with solution and gel preparation was more effective in reducing the size of superficial IH lesions compared to topical ultrapotent corticosteroids.¹¹

There are several mechanisms of action of beta-blockers in the treatment of IH. Beta-adrenergic receptors on IH endothelial cells cause vasoconstriction, decrease blood supply to the lesions. Beta-blockers inhibit angiogenesis by reducing the expression of VEGF, bFGF, MMP-2, and MMP-9 inducing apoptosis of endothelial cells.⁵

Treatment guidelines have not been established for hemangioma therapy with timolol; it is recommended that the dose be limited to <0.25 mg/kg/day. Infants weighing < 2500 g and with a postmenstrual age of < 44 weeks may be at increased risk of side effects such as bradycardia, hypotension, apnea, and hypothermia. Application to mucosal surfaces and ulcerated skin

areas may also increase the potential for systemic absorption and resultant side effects.⁸

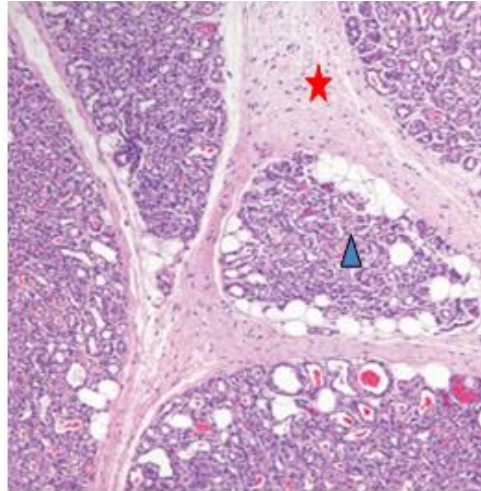


Figure 1. Histologic features of a proliferating infantile hemangioma. Collections of endothelial cells forming vascular lumens (▲), separated by fibrotic septae (★). The inset shows positive GLUT1 staining of endothelial cells⁸

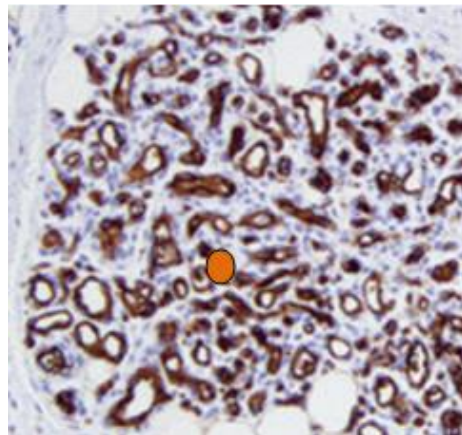


Figure 2. Immunohistochemical analysis shows positive GLUT1 staining of endothelial cells⁸

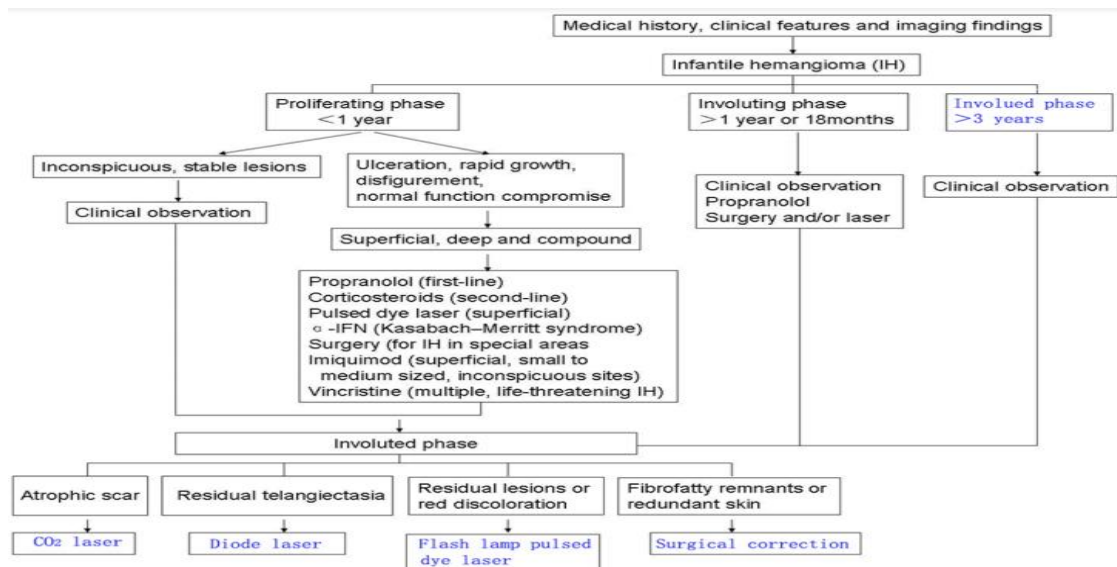


Figure 3. Algorithm management of IH¹⁰

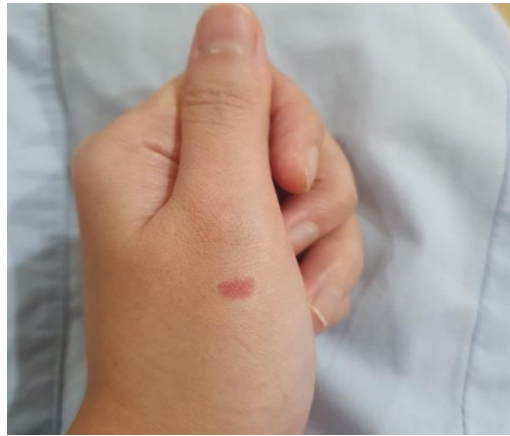
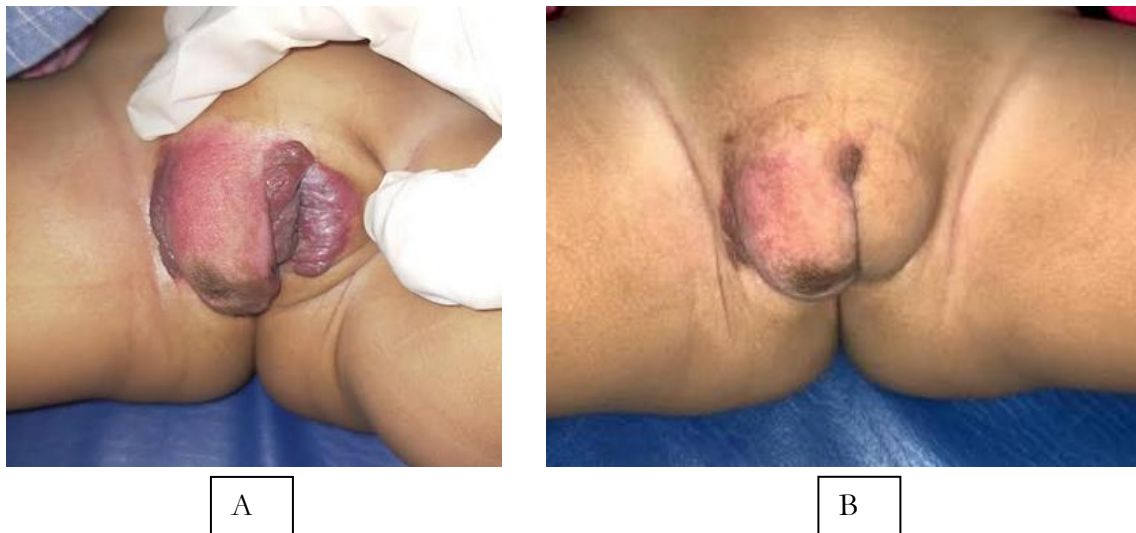
Figure 4. Active Non Intervention approach to superficial IH in the left dorsum manus (courtesy by author)



A

B

Figure 5. Ulcerated superficial hemangioma treated with topical timolol; a. An ulcerated superficial infantile hemangioma on genital of a nine months old girl (Baseline); B. Eight weeks after application of topical timolol solution 0,5%, with one small drop applied twice daily. Healing of the ulcer, as well as the lighter colour and decrease thickness of the hemangioma (Source: primary data by author).

Corticosteroids

Intralesional and topical corticosteroids were commonly used to treat localized IHs. However, these modalities are now utilized less frequently, considering the efficacy of β -blockers. Intralesional corticosteroids are typically employed for small focal lesions. Corticosteroids inhibit new blood vessels in IH tissue. Corticosteroids also inhibit the expression of proangiogenic proteins, including VEGF-A,

plasminogen urokinase activator receptor, chemoattractant protein monocytes, IL-6, and MMP-1, from stem cell tissue in the study model. Corticosteroids also play a role in suppressing NF- κ B as an activator of VEGFR-2.^{3,4}

Systemic absorption may occur, but it is believed to be less than with oral corticosteroids when small lesions are treated. It is recommended that the total dose of triamcinolone not exceed 3–5 mg/kg per

treatment session. In a few case reports and one series of 34 patients, an ultrapotent class 1 topical corticosteroid was utilized to treat periocular hemangiomas and other lesions with an external component. Cessation of growth decreased size/thickness, and lightening of the colour of the hemangioma was observed in 74% of the patients, and there were no significant side effects.⁸

Imiquimod

A retrospective study by Ho reported the effectiveness of topical imiquimod in 18 IH patients. Ten patients took imiquimod three times per week, and eight patients used it five times per week for 17 weeks. Superficial IH experienced resolution, while patients with deep and mixed IH experienced no significant changes. There were mild side effects of irritation and crusting.³ Alakeel reported nine systematic reviews and meta-analyses of imiquimod therapy in IH patients. The results showed that 20.9% of IH lesions resolved. Superficial IH patients have the best resolution of lesions.¹²

The mechanism action of imiquimod starts from a local immune response changing the stimulation of the innate immune system by increasing the production of cytokines, including interferon (α , β , and γ), IL-10, IL-12, and IL-18; and TNF. These agents boost cell-mediated immunity and cause apoptosis. The therapeutic effect of imiquimod on IH from inhibition of angiogenesis by this cytokines. Besides, imiquimod downregulates proangiogenic factors such as bFGF and MMP-9 and regulates endogenous angiogenesis inhibitors, including interferon-inducible protein 10, tissue MMP inhibitors, and thrombospondine.³

Lauromacrogol

Lauromacrogol is the treatment of varicosity. During usage, the local injection of lauromacrogol blocks the blood supply to IHs and destroys vascular endothelial cells, causing embolization of blood vessels and necrosis. Yu et al. reported that 56 IH patients were injected with 1% lauromacrogol once every four weeks for five months. There was a therapeutic response in

85.75% of patients. Side effects of lauromacrogol include scar and ulceration. Lauromacrogol is only recommended as adjuvant therapy for IH.¹³

Systemic Therapies

Systemic therapy of IH which can interfere vitally and the airway functions; potential for organ damage, extensive and recalcitrant ulceration; and heart failure. Systemic treatments include β -blockers, corticosteroids, and vincristine. Currently, reports that rapamycin and recombinant interferon- α are also useful as IH therapy.^{2,8}

β -blockers

In 2014, propranolol (Hemangeol™) became the first FDA-approved treatment for proliferating IHs that require systemic therapy.⁸

Moyakine et al. report case-control study in 82 patients IH with a history of ≥ 6 months of propranolol administration during the infantile period. The results of the study showed no impairing growth.¹⁴

The consensus and FDA recommendations for the use of propranolol in IH patients. Initial dose of 1 mg/kg/day, increasing the dose to 2-3 mg/kg/day for 6-12 months. Tapering dosage when the clinical improvement of the lesion occurred follow-up to assess recurrence of IH, 25% IH lesions can be recurrent after discontinuation of propranolol.^{8,15}

Propranolol can cause mild and severe side effects. Mild side effects include sleep disturbances, cold extremities, and diarrhoea. Severe side effects include hypoglycemia and seizures; bradycardia and hypotension; and bronchospasm.¹⁵ Examination with neurologist, pulmonologist and cardiologist to rule out cardiovascular anomalies, bronchospasm, PHACE syndrome, and patients prone to hypoglycemia before taking propranolol therapy.¹⁵

Corticosteroids

Systemic corticosteroids, usually prednisolone or prednisone, were traditionally employed for the treatment for life- or function-threatening

hemangiomas. Corticosteroids suppress VEGF production by hemangioma-derived stem cells and inhibit vasculogenesis in a murine model. Prednisolone led to a faster response, but propranolol was better tolerated, with significantly fewer adverse events.⁸

Initial dosages of prednisone (or its equivalent) of 2–3 mg/kg/day are most frequently utilized. Treatment is usually maintained at these doses until the cessation of growth or shrinkage occurs, followed by a gradual taper. Benneth et al. reported a systematic review assessing the effectiveness of systemic corticosteroid therapy for proliferating IHs found a response rate of 84% when a mean dose of 2,9 mg/kg/day was used for a mean of 1,8 months before tapering.⁸ Ali et al. reported 60 superficial IH patients < 6 years old were treated with oral propranolol versus prednisone for 12 months. Response therapy in 70% of patients with oral propranolol, and 40% of patients with prednisone. Side effects of facial cushingoid in three patients.¹⁶

Side effects of systemic corticosteroids in children include facial cushingoid, irritability, sleep disturbances, gastrointestinal symptoms, hypertension, hypothalamic-pituitary-adrenal suppression, and decreased growth rates in height and weight.⁸

Vincristine

A chemotherapeutic agent that has been widely used for the treatment of childhood neoplasms. It is a vinca alkaloid that interferes with microtubule formation during mitosis, inducing apoptosis of tumour and endothelial cells. There are reports of its use to treat life or function threatening IHs and other vascular tumours that are unresponsive to corticosteroids. Toxicities include peripheral neuropathy, constipation, jaw pain, anaemia and leukopenia.^{3,8}

Rapamycin

Rapamycin or sirolimus is a macrolide, that has immunosuppressant and antiangiogenic effects.³ Rapamycin blocks the mTOR signalling pathway, which plays a vital role in cell growth and proliferation,

thereby preventing the formation of new blood vessels and causing regression of blood vessels in vitro.⁴

Kaylani reported successful oral rapamycin treatment of an IH recalcitrant to conventional therapy in a child with PHACE(S) syndrome. Potential adverse effects include mucositis, hyperlipidemia, headaches, hepatotoxicity, and neutropenia.⁸

Osorio reported four months old patient was treated with sirolimus at a dose of 0.8 mg / m² twice daily. After three months of sirolimus therapy, resolution of IH lesions occurred. Side effect includes stomatitis and a slight increase in triglyceride levels was found.¹⁷

Recombinant interferon-α

Therapy represents a historical treatment for severe, recalcitrant IHs, but it is now rarely used. The initial dose of interferon-α 1 million IU/m² subcutaneously. The amount was increased to 3 million IU/day during the first month of therapy with follow-up neurologic status, white blood cell count, and hepatic function. The duration of treatment is 2-12 months. Side effects included flu, rash, gastrointestinal disturbances, neutropenia, and spastic diplegia.^{3,8}

Zhang reported administering interferon-α in 11 segmental IH patients for three months. The response occurs in 95% IH resist to steroids and propranolol, but recurrences may occur when therapy discontinued.¹⁸

Laser

Pulsed Dye Laser

Pulsed dye laser (PDL) therapy (585–600 nm wavelength, usually 0,45– 1,5 ms pulse duration) is useful for the treatment of capillary malformations. In the case of proliferating IHs, laser therapy appears to have the most benefit for superficial lesions. Adverse reactions can include pigmentary alteration, ulceration, and atrophic scarring.¹⁹ The PDL also useful for the treatment of telangiectasias on the surface of involuting and involuted hemangiomas.⁸

Reddy reported a retrospective study, infants treated with PDL plus oral propranolol improved more rapidly than those who received propranolol

monotherapy, with near-complete clearance at means of 92 and 288 days, respectively. Shen reported 13 articles with 1529 hemangioma lesions obtaining 89,1% resolution after PDL.²⁰

CO₂ Laser

Carbon dioxide (CO₂) laser is an ablative laser that functions for the treatment of scarring, photodamaged skin, and dyschromia. The CO₂ laser can be used as an atrophic scar therapy in the involuted phase IH. The side effects of CO₂ laser are associated with the potential for infection, and permanent dyspigmentation.²¹

Fractional photothermolysis causes thermal injury to the epidermis and dermis, which is known as the microthermal zone. This action stimulates new collagen production and myoblast proliferation in the dermis, resulting in tissue remodelling and clinical improvement of IH lesions. Good reported three involuted phase in IH patients with residual fibrofatty tissue. Therapeutic response 50-80% clinical improvement in the colour and thickness of IH lesions.²¹

Diode laser

The 532 nm diode laser can be used as IH therapy with residual telangiectasias. Diode laser was well tolerated, and no side effects were reported. Based on the theory of selective photothermolysis, chromophore target in vascular lesions is oxyhemoglobin. After the laser absorbed by oxyhemoglobin, light energy will be converted into heat energy. Heat energy is delivered by diffusion into blood vessels causing selective microvascular damage, then thrombosis of the blood vessel.²²

Cerrati reported 20 IH patients with residual telangiectasias aged 4 months-11 years old were treated with a 532 nm diode laser. Clinical improvement occurred in 73% of patients, and no side effects were reported.²²

Nd: YAG Laser

Nd: YAG or neodymium: yttrium-aluminium-garnet lasers for IH therapy with wavelength 1064 nm and penetration of > 5-6 mm. Lasers are used for deep hemangiomas with percutaneous techniques, the application directly to the skin surface. Side effects include erythema, oedema, bullae, crust, ulceration, hypopigmentation, hyperpigmentation, atrophic scars, and cicatricial alopecia.²³

Elmelegy reported a prospective study of 30 IH patients, mean seven months old, were treated with the Nd: YAG laser and followed up for 7-48 months. The results showed 80% of patients experienced a good response therapy, and 53% of patient's parents were satisfied with the response of treatment.²³

Surgery

Surgical excision is usually employed for involuted or partially involuted lesions to remove fibrofatty tissue and redundant skin. The optimal timing of surgery depends upon multiple factors, including the location, size, and morphology of the lesion. Usually, surgery is performed on patients for ≤ four years.³ In a retrospective study of 112 IHs resected by a single surgeon, 87% of the lesions were located on the head or neck, most excisions by the age of 2-3 year.²⁴

Surgical excision during the proliferative phase is controversial and usually reserved for situations in function threatening hemangioma, e.g. a periocular lesion blocking the visual axis or lip lesion interfering with feeding or speech, failed to respond to pharmacologic therapy; or pharmacologic treatment is believed to pose a greater risk to the patient than surgical excision.²⁵

Hynes compared 21 patients with IH on the lips (10 proliferative phases, 11 involution phases) under surgical excision and followed up for 2 years, found comparable long-term cosmetic outcomes and less speech delay in those undergoing early excision.⁸

Transcatheter Arterial Sclerosing Embolization (TASE)

Arterial embolization has been used to treat life-

threatening hemangiomas.⁸ Segmental IH commonly associated with hepatic hemangioma. Infantile hepatic hemangioma (IHH) is characterized by a hypervascular tumour infused with the hepatic artery. One of modalities therapy is TASE. The criteria of treatment by TASE are hepatic hemangioma with maximal diameter > 4 cm confirmed by ultrasound, CT or MRI. There is no absolute contraindication.²⁶

Patient under general anaesthesia, Seldinger catheterization was performed through the right or left femoral artery. Then the 4 F super Cobra catheter was inserted into the celiac artery through 4 F vascular sheath for Selective Celiac Arteriography. Digital subtraction angiographic (DSA) was performed at the same time to determine the location, number, size, staining characteristics and blood supply of the IHH. Then the 2.6 F micro-catheter was used for super selective catheterization of the feeding artery. After the success, pingyangmycin-lipiodol emulsion (PLE) was injected slowly through the catheter until the periphery of the hemangioma was surrounded. The injection was stopped when a small branch of portal vein around the tumour was development, or the total volume was administered. Wu et al. reported 11 IHH patients with TASE, found tumour size decreased after five months of therapy.²⁶

Prognosis

Infantile hemangiomas involute spontaneously at 5-9 years old with or without sequelae. Spontaneous regression by the age of 5-9 years. 50% of all hemangiomas will completely involute by the age of 5 years and 90% by the age of 9 years. Sequelae occurred in 40% of involuted lesions may either show scarring, wrinkling, telangiectasia, or loose fibro-fatty tissue.^{27,28} Bauland et al. reported 97 untreated IH patients, found 70% of patients got sequelae. An important factor affecting the prognosis is the timing of initial treatment taking.²

2. Conclusion

The management of IH is influenced by several factors, including location, the morphology of the

evolutionary phase, impaired organ function, risk of disability and morbidity. Also, age, psychosocial effects, and choice of therapy by parents influence the management of IH. An approach of IH management includes active non-intervention and active intervention. Active non-intervention is carried out small IH with a good prognosis because it can make a spontaneous resolution. Meanwhile, active intervention is carried out if IH lesion with a greater risk of developing local or systemic complications. Active interventions include topical and systemic pharmacological agents, laser therapy, surgery, and TASE. The FDA has approved propranolol as first-line therapy with good response, but adequate monitoring of treatment is required.

3. References

1. Harbi S, Wang R, Gregory M, Hanson N, Kobylarz K, Ryan K, et al. Infantile hemangioma originates from a dysregulated but not fully transformed multipotent stem cell. *J Sci Rep.* 2016;6:1-17.
2. Macarthur KM, Puttgen K. Vascular Tumors. In: Kang S, Amagai M, Bruckner AL, Enk AH, Margolis DJ, McMichael AJ, Orringer JS, editors. *Fitzpatrick's Dermatology.* 9th ed. New York: McGraw-Hill Company; 2019: p. 2042-70.
3. Darrow DH, Greene AK, Mancini AJ, Nopper AJ. Diagnosis and management of infantile hemangioma. *J Pediatrics.* 2015;136(4):1060-104.
4. Rosenblatt A, Mathes EF, Rosbe KW. Infantile hemangiomas: from pathogenesis to clinical features. *J Res Rep Neonatol.* 2012;2:55-64.
5. Rotter A, Najjar Z, Oliveira P. Infantile hemangioma: pathogenesis and mechanisms of action of propranolol. *J Dtsch Dermatol Ges.* 2017;1185-90.
6. Higgins EM, Glover MT. Dermatoses and Haemangiomas of Infancy. In: Griffith C, Barker J, Bleiker T, Chalmers R, Creamer D, editors. *Rook's Textbook of Dermatology.* 9th ed. United Kingdom: John Wiley & Sons; 2016. p. 117.17-25.

7. Callahan AB, Yoon MK. Infantile hemangioma: a review. *Saudi J Ophthalmol.* 2012;26: 283-91.
8. Haggstrom AN, Garzon MC. Infantile Hemangiomas. In: Bologna JL, Schaffer J, Cerroni L, editors. *Dermatology.* 4th ed. New Haven: Elsevier Limited; 2018. p. 1786-1804.
9. Yang G, Kang J, Zhu M, Wang S. Magnetic resonance diffusion-weighted imaging and computed tomography in the diagnosis of hemangioma and venous malformations of head and neck among children. *Int J Clin Exp Med.* 2016;9(1):131-9.
10. Zheng JW, Zhang L, Zhou Q, Mai HM, Wang YA, Fan XD, et al. Review article a practical guide to treatment of infantile hemangiomas of the head and neck. *Int J Clin Exp Med.* 2013;6(10):851-60.
11. Danarti R, Ariwibowo L, Radiono S, Budiyo A. Topical timolol maleate 0,5% for infantile hemangioma: its effectiveness compared to ultrapotent topical corticosteroids-a single-center experience Of 278 cases. *J Dermatol.* 2016;232:566-71.
12. Alakeel A. Safety and efficacy of imiquimod in the treatment of infantile hemangioma; a systematic review and meta-analysis. *J Curr Med Res Op.* 2020;3(3):430-8.
13. Chen ZY, Wang QN, Zhu YH, Zhou LY, Xu T, He ZY, et al. Progress in the treatment of infantile hemangioma. *Ann Transl Med.* 2019;7(22):692-708.
14. Moyakine AV, Kerstjens JM, Spillekom-van Koulil S, van der Vleuten CJ. Propranolol treatment of infantile hemangioma (IH) is not associated with developmental risk or growth impairment at age 4 years. *J Am Acad Dermatol* 2016;75:59–63
15. Rademaker M, Fischer G, Bekhor P, Lokmic Z. Consensus statement for the treatment of infantile haemangiomas with propranolol. *Australasian J Dermatol.* 2017;1-6.
16. Ali A, Aiman U, Haseen A, Mir MA, Ghani I, Bharadwaj R, et al. The effect of oral propranolol versus oral corticosteroids in management of pediatric hemangiomas. *World J Plast Surg.* 2018;7(1):16-24.
17. Osorio VLD, Iznardo H, Roe E, Puig L, Baselga E. Propranolol-resistant infantile hemangioma successfully treated with sirolimus. *J Ped Dermatol.* 2020:1-3.
18. Zhang L, Zheng JW, Yuan WE. Treatment of alarming head and neck infantile hemangiomas with interferon- α 2a: a clinical study in eleven consecutive patients. *J Drug Des Devel Ther.* 2015;9:723-7.
19. Ying MS, Tay YK. Laser treatment of infantile hemangiomas. *Indian J Paediatr Dermatol.* 2017;18:160-5.
20. Shen L, Zhou G, Zhao J, Li P, Xu Q, DongY, et al. Pulsed dye laser therapy for infantile hemangiomas: a systemic review and meta-analysis. *Q J med.* 2015;108:473-80.
21. Good E, Kirkorian AY, Bauman NM, Rubin IK. Fractionated CO₂ laser treatment to reduce fibrofatty tissue bulk of involuted infantile hemangiomas: a case series. *Ann Plast Reconstr surg.* 2019;3(5):1045-8.
22. Cerrati EW, March TM, Chung H, Waner M. Diode laser for the treatment of telangiectasias following hemangioma involution. *Am J Otolaryngol Head Neck Surg.* 2014;1-5.
23. ElMelegy N, Mahmoud WH, ElHawary AY. Evaluation of the use of Nd:YAG laser in the treatment of infantile hemangiomas. *J Plast Reconstr Surg.* 2017; 41(2):311-17.
24. Lee AH, Hardy KL, Goltsman D, et al. A retrospective study to classify surgical indications for infantile hemangiomas. *J Plast Reconstr Aesthet Surg.* 2014;67:1215–21.
25. Purwanthi IGAP, Rooseno RRN. Resection of localized cheek infantile hemangioma in the proliferative phase: a case report. *Int J Res med Sci.* 2018;6(10):1-4.
26. Wu C, Li X, Wang L, Li J, Song D, Wang C. Interventional embolization in treatment of

- infantile hepatic hemangiomas. *Int J Clin Exp Med*. 2018;11(10): 11277-82.
27. George A, Mani V, Noufal A. Update on the classification of hemangioma. *J Oral Maxillofac Pathol*. 2014;18(1):117-20.
28. Krowchuk DP, Frieden IJ, Mancini AJ, Darrow DH, Blei F, et al. Clinical practice guideline for the management of infantile hemangioma. *J Pediatr*. 2019;143(1):1-28.