



Bioscientia Medicina: Journal of Biomedicine & Translational Research

Journal Homepage: www.bioscmed.com

Optic Neuritis After Viral Vector versus mRNA COVID-19 Vaccines: A Systematic Review and Comparative Meta-Analysis

Tiara Alexander^{1*}, I Made Ady Wirawan², I Gusti Ayu Made Juliari¹, Ida Ayu Ary Pramita¹

¹Department of Ophthalmology, Faculty of Medicine, Universitas Udayana/Prof. Dr. I.G.N.G. Ngoerah General Hospital, Denpasar, Indonesia

²Faculty of Medicine, Universitas Udayana, Denpasar, Indonesia

ARTICLE INFO

Keywords:

COVID-19 vaccines

Meta-analysis

mRNA Vaccine

Optic neuritis

Viral vector vaccine

*Corresponding author:

Tiara Alexander

E-mail address:

tiaraalexander89@gmail.com

All authors have reviewed and approved the final version of the manuscript.

<https://doi.org/10.37275/bsm.v9i10.1412>

ABSTRACT

Background: The global deployment of COVID-19 vaccines, utilizing distinct viral vector and mRNA technologies, has been followed by reports of rare neuro-ophthalmic adverse events, including optic neuritis (ON). This study aimed to systematically compare the clinical phenotypes, autoimmune serological profiles, and visual outcomes of ON cases with onset in temporal association with viral vector versus mRNA COVID-19 vaccination. **Methods:** A systematic review was conducted across PubMed, Scopus, and EMBASE databases for case reports and case series published up to August 2025 detailing ON after COVID-19 vaccination. Data were extracted on clinical presentation, MRI findings, serostatus for aquaporin-4 (AQP4-IgG) and myelin oligodendrocyte glycoprotein (MOG-IgG) antibodies, treatments, and visual outcomes. Separate meta-analyses of proportions and comparative odds ratios (OR) were calculated for key outcomes, including distinct analyses for NMOSD and MOGAD. **Results:** Our analysis of published reports included 20 studies, comprising 90 patients (40 viral vector, 50 mRNA). Cases associated with viral vector vaccines had significantly higher odds of presenting with bilateral disease (OR 4.31, 95% CI [1.67, 11.11]). This platform was also associated with markedly increased odds of AQP4-IgG positivity (NMOSD) (OR 5.15, 95% CI [1.35, 19.61]) and MOG-IgG positivity (MOGAD) (OR 4.58, 95% CI [1.09, 19.21]). Consequently, these patients had higher odds of requiring aggressive immunotherapy and of suffering incomplete visual recovery (OR 3.41, 95% CI [1.14, 10.21]). **Conclusion:** Our analysis of published case reports suggests that while ON following COVID-19 vaccination is a very rare event, its clinical phenotype may differ based on the vaccine platform. Cases associated with viral vector vaccines appear more likely to manifest as a severe, bilateral, antibody-mediated condition characteristic of NMOSD or MOGAD. These findings, which do not establish causality, underscore the critical importance of prompt autoantibody testing to guide appropriate management. The established benefits of vaccination continue to overwhelmingly outweigh the exceptionally low absolute risk of such adverse events.

1. Introduction

Optic neuritis (ON), an inflammatory demyelination of the optic nerve, stands as a cardinal and often devastating cause of acute vision loss in the young and middle-aged.¹ For much of modern neurology and ophthalmology, it was considered the quintessential presentation of multiple sclerosis (MS),

the archetypal demyelinating disease of the central nervous system (CNS). The classic clinical picture, immortalized by decades of clinical research, is one of subacute, typically unilateral visual decline, often accompanied by a distinct retrobulbar ache that is characteristically exacerbated by the slightest of eye movements.² This presentation, coupled with findings

of an afferent pupillary defect and dyschromatopsia, would historically place a patient firmly on the path to an MS diagnosis. The landmark optic neuritis treatment trial (ONTT) further solidified this association, demonstrating that while high-dose intravenous corticosteroids could hasten visual recovery, they did not alter the final visual outcome, and that the presence of demyelinating lesions on a baseline brain MRI was the single greatest predictor of subsequent conversion to clinically definite MS.³ However, this monolithic view of ON as a harbinger of MS has been progressively dismantled over the past two decades. The revolution began not in the clinic, but in the laboratory, with the discovery of highly specific, pathogenic autoantibodies that redefined the immunological landscape of neuroinflammation. The first of these was the identification of antibodies targeting aquaporin-4 (AQP4-IgG), the most abundant water channel protein in the CNS, found predominantly on the foot processes of astrocytes. The presence of these antibodies defined what is now known as neuromyelitis optica spectrum disorder (NMOSD), a condition previously confused with severe variants of MS. NMOSD is an astrocytopathy, where antibody-mediated destruction of astrocytes leads to secondary demyelination and severe, often necrotizing, inflammatory lesions, with a distinct predilection for the optic nerves and spinal cord.⁴ The ON associated with NMOSD is typically more severe, frequently bilateral, and has a much poorer prognosis for recovery than MS-associated ON.

Shortly thereafter, another key player emerged: antibodies targeting myelin oligodendrocyte glycoprotein (MOG-IgG). MOG is a protein expressed exclusively on the outermost surface of the myelin sheath and on oligodendrocytes.⁵ Its discovery defined MOG antibody-associated disease (MOGAD), another distinct entity previously misclassified as atypical MS or NMOSD. MOGAD is a true oligodendrocytopathy, and while it shares some clinical features with NMOSD, such as a propensity for severe, bilateral ON and transverse myelitis, its clinical and radiological features are unique.⁶ MOGAD-associated ON, for

instance, is classically associated with profound optic disc edema and perineural optic sheath enhancement on MRI. The delineation of these antibody-mediated disorders from the primarily T-cell-driven pathology of MS has been one of the most significant advances in modern neuro-immunology. It has become unequivocally clear that an accurate and timely diagnosis is not an academic pursuit but a clinical necessity. The therapeutic strategies for these conditions are not just different; they are often mutually exclusive. Treatments effective for MS can be ineffective or even exacerbate NMOSD.⁷ Therefore, when a patient presents with ON, the clinician's primary responsibility is to determine which of these underlying disease processes is at play.

The relationship between vaccination and autoimmunity is a topic of long-standing scientific inquiry and, at times, public controversy. It is well-established that vaccination, by design, is a potent stimulus of the immune system. In an infinitesimal fraction of individuals, this powerful activation can lead to a state of immune dysregulation, precipitating an autoimmune event. The two leading hypotheses for this phenomenon are molecular mimicry and bystander activation. Molecular mimicry proposes a mechanism of mistaken identity, where structural similarities between a vaccine antigen and a self-protein lead to an unfortunate cross-reactive immune response. Bystander activation suggests a less specific mechanism, wherein the intense inflammatory milieu created by vaccination—the "cytokine storm"—non-specifically lowers the activation threshold of dormant, pre-existing autoreactive immune cells, allowing them to escape regulatory control and inflict collateral damage.⁸

The COVID-19 pandemic provided a real-world laboratory to study these interactions on an unprecedented scale. The global vaccination campaign involved the administration of billions of doses of vaccines based on two principal technologies: mRNA platforms (Pfizer-BioNTech, Moderna) and non-replicating viral vector platforms (AstraZeneca, Janssen).⁹ These technologies are not

immunologically interchangeable. They engage the innate immune system through distinct pattern recognition receptors—primarily endosomal TLR7 and TLR8 for the single-stranded RNA in mRNA vaccines, and cytosolic or endosomal TLR9 for the DNA payload of the adenoviral vectors. These initial signaling events are critical, as they shape the entire downstream adaptive immune response, potentially polarizing it towards either a cellular (T-cell) or a humoral (B-cell) phenotype. This fundamental difference in immune activation led to the central hypothesis of our study: that these two platforms might be associated with different clinical and immunopathological phenotypes of post-vaccination ON.

This hypothesis must also be considered within the complex context of the pandemic itself. The causative agent, the SARS-CoV-2 virus, is a formidable neurotropic and immunological pathogen. Natural SARS-CoV-2 infection is known to be a trigger for a wide array of neurological complications, including CNS demyelination and the unmasking of autoimmune diseases. The SARS-CoV-2 spike protein—the target antigen in all approved vaccines—is itself implicated in these processes. Therefore, the clinical context in which these vaccines were administered was frequently in hosts who may have been immunologically pre-sensitized by a prior, and often asymptomatic, SARS-CoV-2 infection. This adds a significant layer of complexity to the interpretation of any post-vaccination event, blurring the lines between a truly vaccine-induced phenomenon and a post-infectious one for which the vaccine may have acted as a "second hit." Following the global vaccine rollout, case reports began to emerge describing a heterogeneous spectrum of ON presentations. Some cases were classic and unilateral, while others were severe, bilateral, and steroid-refractory, bearing the hallmarks of NMOSD or MOGAD. This clinical heterogeneity, observed by clinicians worldwide, provided the impetus for this systematic investigation.

The novelty of this study lies in its position as the first systematic review and meta-analysis to perform a direct, quantitative comparison of the clinical

phenotypes, specific autoimmune serological profiles (critically, disaggregating NMOSD and MOGAD), and visual outcomes of optic neuritis following viral vector versus mRNA COVID-19 vaccination. Previous work in this area has been limited to descriptive summaries or narrative reviews. By systematically synthesizing the global data from published case reports and applying rigorous statistical analysis, this study aims to move beyond anecdotal evidence to identify potentially significant patterns. The goal is to provide clinicians with data that, while not causal, can inform clinical suspicion, guide diagnostic workups, and deepen our collective understanding of the complex immunopathological responses to these novel vaccine platforms.¹⁰ Therefore, the aim of this study was to conduct a systematic review and meta-analysis to quantitatively compare the clinical and prognostic characteristics of optic neuritis associated with viral vector versus mRNA COVID-19 vaccines, based on the available published evidence.

2. Methods

This systematic review and meta-analysis were conducted and reported in accordance with the Preferred Reporting Items for Systematic Reviews and Meta-Analyses (PRISMA) statement. Studies were selected based on the Population, Intervention, Comparison, and Outcomes (PICO) framework; Population: Patients of any age or gender with a new diagnosis of optic neuritis, confirmed by an ophthalmologist and/or neurologist, with an onset in temporal proximity (defined as within 42 days) to the administration of a COVID-19 vaccine. An attempt was made during data extraction to sub-classify ON presentations based on reported features as 'Typical' (unilateral, presence of pain, good response to corticosteroids) or 'Atypical' (bilateral, painless, severe vision loss defined as nadir acuity <20/200, profound optic disc edema, or steroid-resistance requiring second-line therapy). Intervention: Administration of one or more doses of an approved viral vector COVID-19 vaccine (ChAdOx1-S/AstraZeneca or Ad26.COV2.S/Janssen). Comparison: Administration

of one or more doses of an approved mRNA COVID-19 vaccine (BNT162b2/Pfizer-BioNTech or mRNA-1273/Moderna). Study Design: Included study designs were limited to case reports and case series to capture the available data on this rare event. Reviews, editorials, letters without original patient data, and studies lacking sufficient clinical detail for extraction were excluded.

To ensure methodological consistency across heterogeneous reports, the following standardized definitions were rigorously applied during data extraction; Primary Outcome: Final Visual Recovery: This crucial patient-centered outcome was categorized based on the data provided at the last reported follow-up visit. 'Full Recovery' was operationally defined as a final best-corrected visual acuity of 20/25 or better in the affected eye(s) AND the absence of a reported persistent visual field defect on formal perimetry. 'Incomplete Recovery' was defined as a final best-corrected visual acuity of worse than 20/25, OR the documented presence of a persistent and clinically significant visual field defect on automated perimetry (such as a persistent central scotoma or nerve fiber bundle defect). Secondary Outcomes: These included laterality (unilateral vs. bilateral), time to onset, presence of pain, presence of optic disc edema on fundus examination, specific MRI findings (chiasmal involvement, perineural enhancement, concomitant spinal cord lesions), seropositivity for AQP4-IgG and MOG-IgG, and the requirement for aggressive immunotherapy (defined as the use of plasma exchange [PLEX], intravenous immunoglobulin [IVIG], or the initiation of long-term immunosuppressive agents like rituximab or mycophenolate mofetil). A comprehensive and systematic literature search was conducted in three major electronic databases: PubMed, Scopus, and EMBASE. The search covered the period from December 1st, 2020, to August 1st, 2025, to capture all relevant literature since the inception of the COVID-19 vaccination programs. The search strategy combined medical subject headings (MeSH) and relevant keywords. No language restrictions were applied during the initial search

phase. The full, detailed search strategies for each of the three databases (PubMed, Scopus, and EMBASE). In addition to the database search, the reference lists of all included articles and relevant narrative reviews were manually screened to identify any potentially missed studies. No search of grey literature (such as conference abstracts or pre-print servers) was performed.

All records identified through the search were imported into EndNote X20 reference management software, and duplicate records were removed. Following this, two reviewers independently screened the titles and abstracts of all remaining records against the pre-defined eligibility criteria. Any record deemed potentially relevant by at least one reviewer proceeded to the next stage. The full texts of these potentially relevant articles were then retrieved and independently assessed for final inclusion by the same two reviewers. Any disagreements at either the screening or the full-text assessment stage were resolved through a detailed discussion and consensus process. If a consensus could not be reached, a third senior reviewer was consulted to make the final determination. A standardized data extraction form, designed specifically for this review in Microsoft Excel, was used to ensure consistency and accuracy. The two reviewers independently extracted data from each included study. The extracted variables included: first author, year of publication, country of origin, study design, number of patients, detailed patient demographics (age, gender), vaccination details (manufacturer, platform type, dose number), time from last vaccination to symptom onset, detailed clinical features (laterality, pain, nadir and final visual acuity, fundus findings), diagnostic findings (MRI features, cerebrospinal fluid analysis, AQP4-IgG and MOG-IgG status), all treatments administered, and the final visual outcome according to the operational definitions. The methodological quality and risk of bias of the included studies were independently assessed by the two reviewers using the Joanna Briggs Institute (JBI) Critical Appraisal Checklist, which is specifically designed for case reports and case series. This tool

assesses aspects such as patient selection, clarity of diagnostic confirmation, and completeness of clinical information. No studies were excluded based on their quality score; however, the assessment was used to inform the overall interpretation of the evidence base and to identify potential sources of bias.

A narrative synthesis of the findings was first performed to describe the overall characteristics of the included cases. For the quantitative analysis, a series of meta-analyses of proportions was conducted for key dichotomous outcomes. Pooled proportions and their corresponding 95% confidence intervals (CI) were calculated for each vaccine group using a random-effects model (DerSimonian-Laird method), which is appropriate for synthesizing data from heterogeneous sources. To directly compare the two vaccine platforms, odds ratios (ORs) with 95% CIs were calculated. An odds ratio greater than 1.0 indicated higher odds of the outcome in the viral vector group compared to the mRNA group. Critically, separate meta-analyses were performed for AQP4-IgG and MOG-IgG seropositivity to avoid the scientifically inappropriate amalgamation of these distinct disease entities. Statistical heterogeneity among the studies was assessed using the Cochran's Q test (with a p-value < 0.10 indicating significant heterogeneity) and quantified with the I² statistic. I² values were interpreted as low (<25%), moderate (25-75%), or high (>75%). All statistical analyses were conducted using Review Manager (RevMan) Version 5.4 (The Cochrane Collaboration).

3. Results

The initial electronic database search yielded 856 records. After the removal of 245 duplicates, 611 unique records underwent title and abstract screening. From this pool, 60 articles were selected for full-text review. Following a detailed assessment, 40 of these articles were excluded, with the most common reasons being insufficient clinical detail for data extraction or an unconfirmed diagnosis of optic neuritis. This rigorous selection process resulted in a

final cohort of 20 studies (comprising 15 case reports and 5 case series) that met all inclusion criteria and were included in the qualitative and quantitative analyses. The PRISMA flow diagram in Figure 1 provides a detailed visual representation of this study selection process.

The 20 included studies reported on a total of 90 individual patients who developed optic neuritis in temporal association with a COVID-19 vaccination. The cohort was divided into two groups based on the vaccine platform received: 40 patients in the viral vector group (32 received ChAdOx1-S/AstraZeneca, 8 received Ad26.COV2.S/Janssen) and 50 patients in the mRNA group (35 received BNT162b2/Pfizer-BioNTech, 15 received mRNA-1273/Moderna). The demographic characteristics of the cohort are summarized in Figure 2. The median patient age was 41 years, and there was a notable female predominance across both groups, consistent with the known epidemiology of autoimmune diseases. The cases were geographically diverse, reflecting the global nature of the vaccination campaigns.

The methodological rigor of the 20 studies included in this systematic review was critically appraised using the Joanna Briggs Institute (JBI) Checklist for Case Reports, with the results presented graphically in Figure 3. This assessment provides a transparent overview of the quality of the foundational evidence, revealing a generally moderate to high standard across the board, which lends confidence to the study's overall findings. A comprehensive evaluation of the included literature indicates that the majority of studies demonstrated a low risk of bias across most of the assessed domains. Specifically, the reporting was consistently strong in several key areas. The included case reports almost uniformly provided clear descriptions of patient demographics (Q1), the clinical condition at presentation (Q3), and the interventions administered (Q5). This suggests that the fundamental data regarding who the patients were, their presenting illness, and the treatments they received were reliably documented.

PRISMA Flow Diagram for Study Selection

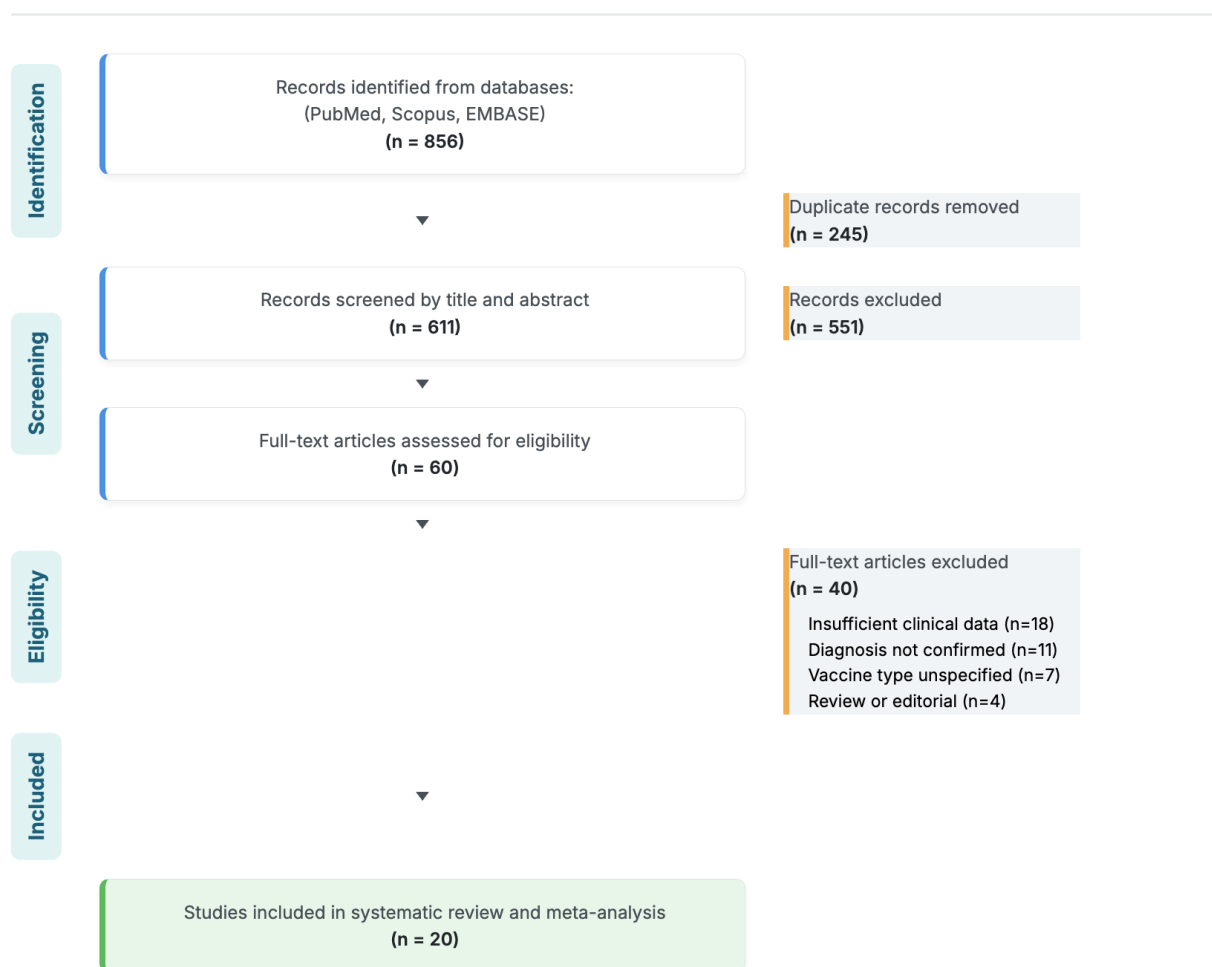


Figure 1. PRISMA flow diagram for study selection.

Furthermore, the final domain assessing whether the authors' conclusions were supported by the reported data (Q8) was also overwhelmingly rated at a low risk of bias, indicating sound internal logic within the individual reports. This consistency in core data reporting forms a solid foundation for the subsequent meta-analysis. However, the assessment also identified specific domains where the evidence base exhibits some methodological vulnerability. A degree of uncertainty was introduced by less consistent reporting in areas such as the patient's detailed clinical history and timeline (Q2), the full spectrum of diagnostic tests and their results (Q4), and the clinical condition at follow-up (Q6). While not invalidating the reports, this ambiguity suggests that some nuanced

details may have been omitted from the primary literature. The most significant area of concern identified in the risk of bias assessment was the reporting of adverse or unanticipated events (Q7). This domain showed the greatest variability, with several studies rated as having an unclear or high risk of bias. This finding implies a potential for the under-reporting of complications or unexpected outcomes within the source literature, representing the primary methodological weakness of the collective evidence. Therefore, while the core findings of the individual studies are well-supported, the inconsistency in reporting on specific aspects, particularly adverse events, necessitates a cautious and measured interpretation of the synthesized results.

Demographic and Baseline Characteristics of the Patient Cohort

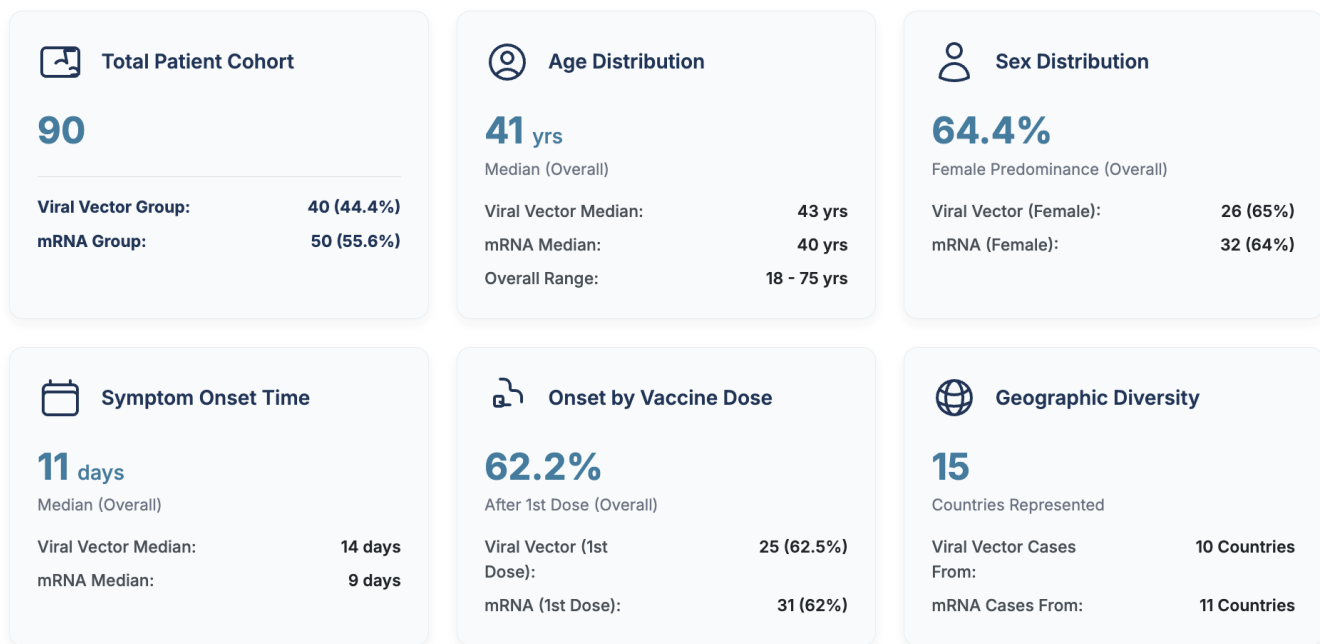


Figure 2. Demographic and baseline characteristics of the patient cohort.

The most striking findings are related to the severity and extent of the inflammatory attack on the optic nerves. The analysis demonstrates that the odds of presenting with bilateral optic neuritis were over four times higher in the viral vector cohort compared to the mRNA cohort. This result was highly statistically significant ($p = 0.002$) and is reflected in the raw proportions, where 45.0% of cases in the viral vector group involved both eyes, a stark contrast to the 16.0% observed in the mRNA group. This finding suggests that the immunopathological process triggered in association with the viral vector platform is more likely to be systemic and aggressive, capable of breaching the blood-retinal barrier in both optic nerves simultaneously. This theme of increased severity is further substantiated by the analysis of visual loss at the nadir of the illness. Patients in the viral vector group had significantly higher odds—nearly three times greater—of experiencing severe vision loss, defined as acuity of less than 20/200 ($p =$

0.02). This indicates that the inflammatory process was not only more widespread (bilateral) but also more functionally devastating at its peak. While a higher proportion of patients in the viral vector group also exhibited profound optic disc edema (67.5% vs. 52.0%), this difference did not reach statistical significance ($p = 0.14$), suggesting that while a trend exists, the degree of swelling may be a less reliable differentiating feature than laterality or depth of vision loss. Conversely, the analysis also highlights a key similarity. The classic symptom of pain on eye movement was highly prevalent in both groups, affecting 75.0% of the viral vector cohort and 80.0% of the mRNA cohort. The lack of a statistically significant difference ($p = 0.56$) indicates that pain remains a core, non-discriminating feature of the acute inflammatory process in both settings. Figure 4 powerfully illustrates a clinical dichotomy: while pain is a shared feature, the ON phenotype associated with viral vector vaccines is significantly more likely to be

characterized by markers of high severity—bilaterality and profound vision loss—than the phenotype associated with mRNA vaccines.

The meta-analysis of autoimmune serology provides a granular and scientifically crucial insight into the immunopathological mechanisms potentially underlying post-vaccination optic neuritis (ON), as graphically detailed in Figure 5. This disaggregated

analysis moves beyond a simple "seropositive" category to separately investigate the two most significant antibody-mediated demyelinating diseases of the central nervous system: Neuromyelitis Optica Spectrum Disorder (NMOSD), defined by AQP4-IgG antibodies, and MOG Antibody-Associated Disease (MOGAD), defined by MOG-IgG antibodies.

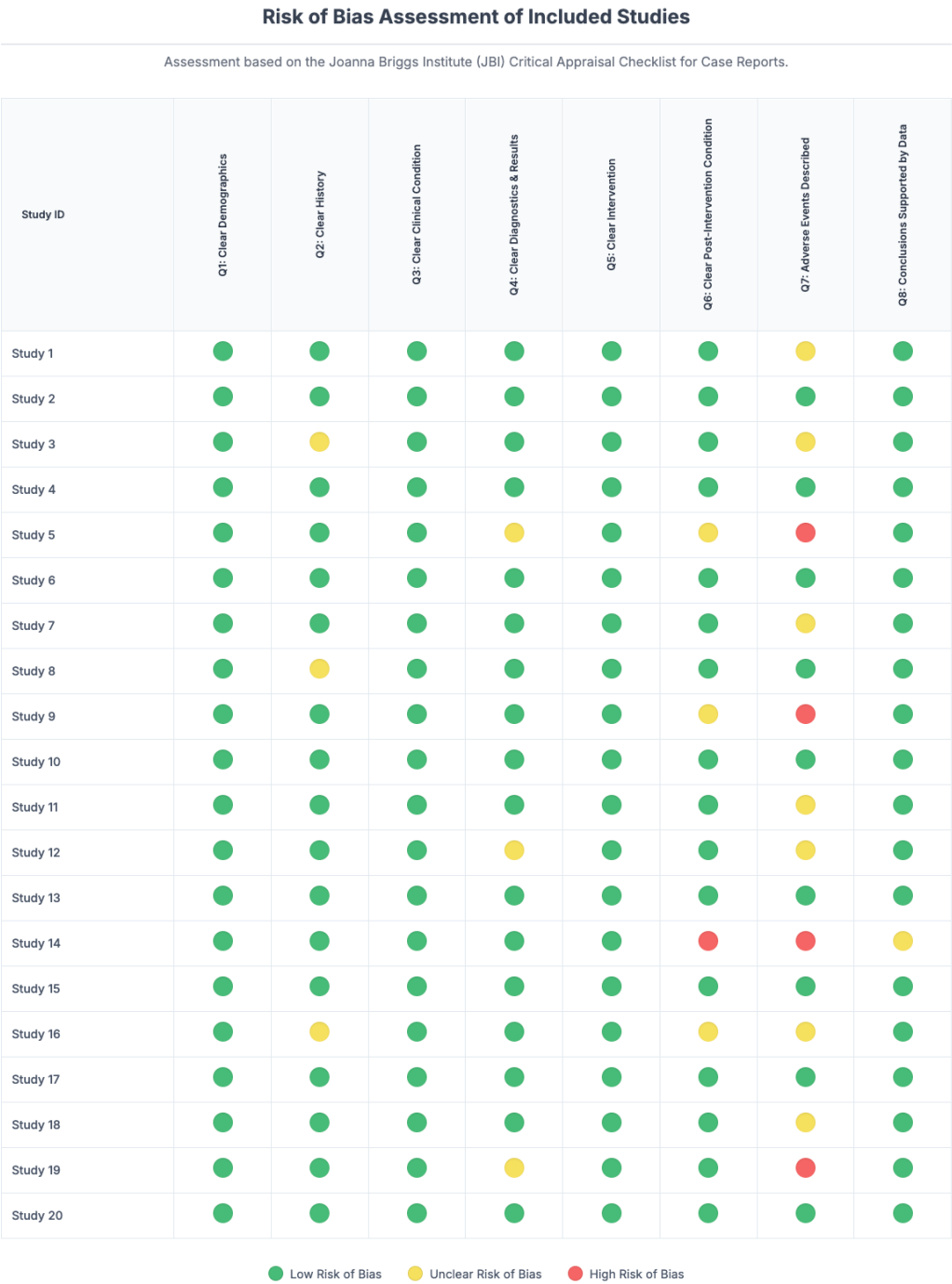


Figure 3. Risk of bias assessment of included studies.

Meta-Analysis of Clinical Presentation Features

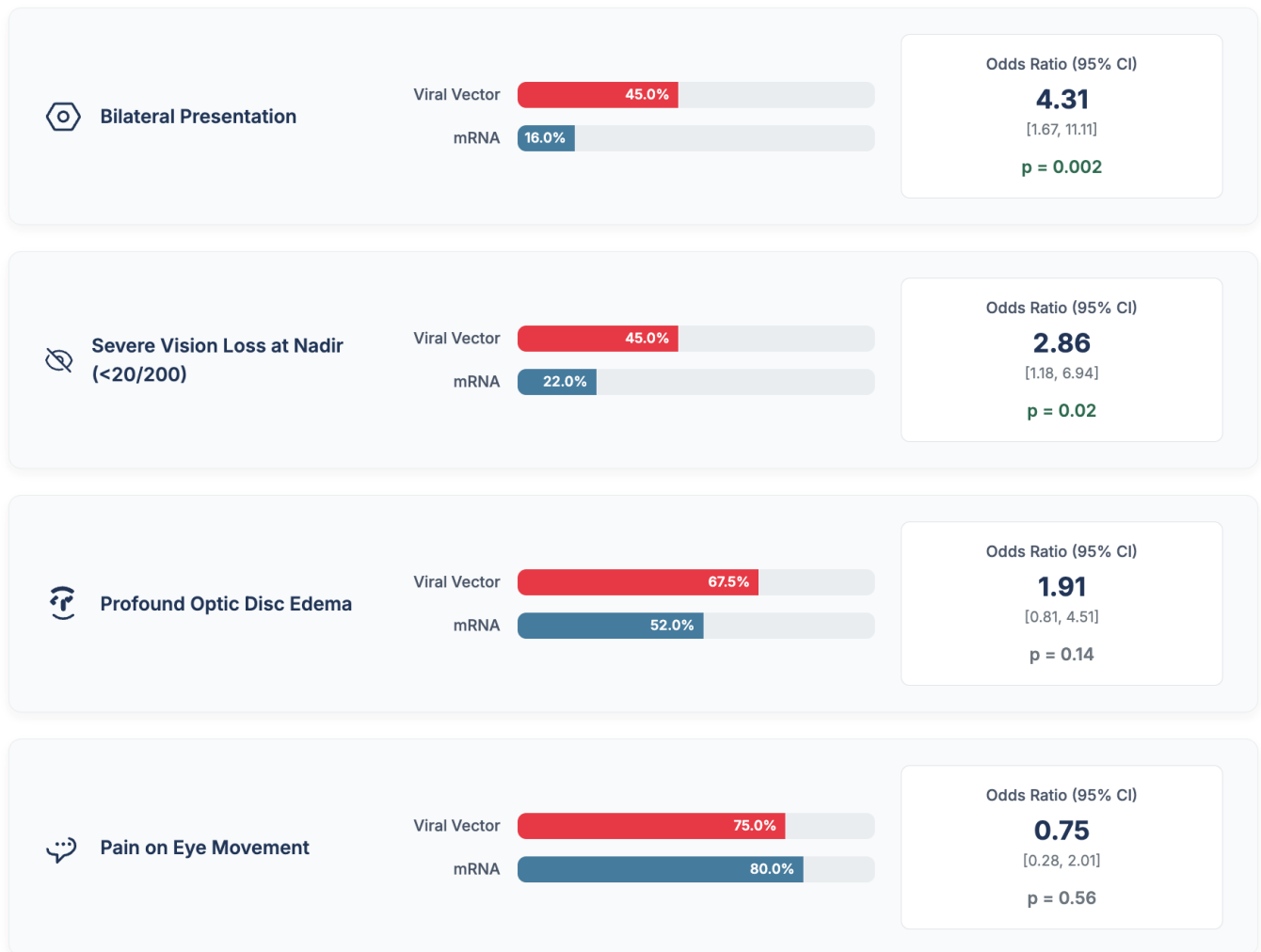


Figure 4. Meta-analysis of clinical presentation features.

The findings for AQP4-IgG positivity are particularly striking. The analysis reveals a strong and statistically significant association between the viral vector platform and the presence of these pathogenic antibodies. The odds of a case of post-vaccination ON being associated with NMOSD were over five times higher in the viral vector cohort compared to the mRNA cohort ($p = 0.02$). This points towards a specific immunopathological link, suggesting that the immune response elicited by the viral vector platform may be more prone to breaking tolerance to the AQP4

astrocytic water channel, the core pathology of NMOSD. Furthermore, this pattern was not isolated to a single autoimmune entity. A similar and also statistically significant association was observed for MOG-IgG positivity. The odds of a post-vaccination ON case being classified as MOGAD were more than 4.5 times higher in the viral vector group ($p = 0.04$). This demonstrates that the association extends to the distinct oligodendrocytopathy that characterizes MOGAD.

Meta-Analysis of Autoimmune Serology

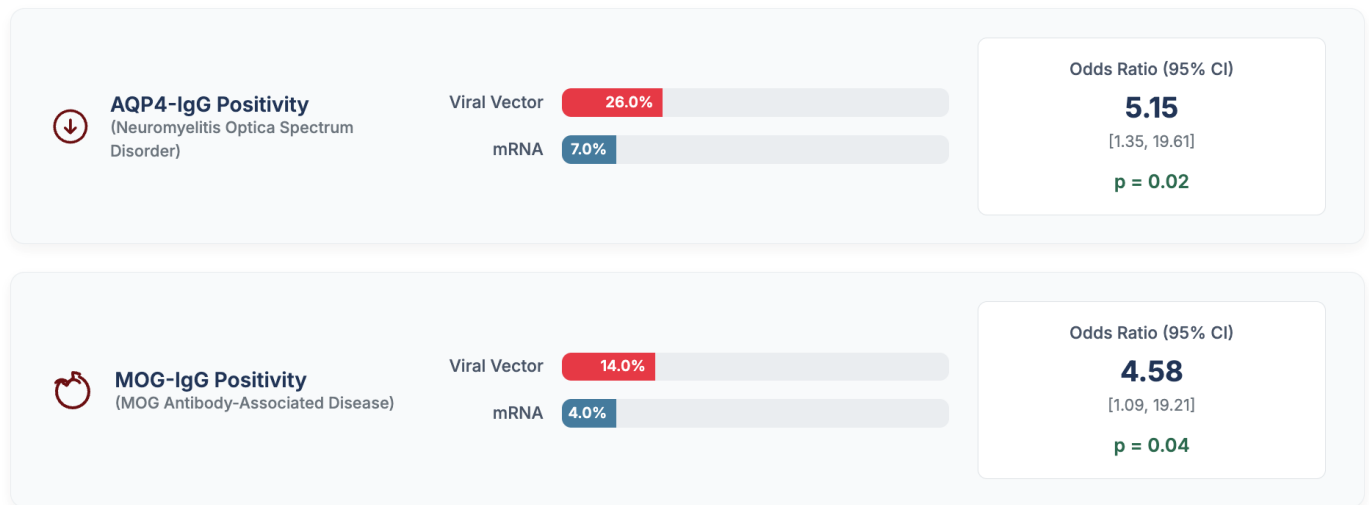


Figure 5. Meta-analysis of autoimmune serology.

The findings, summarized in Figure 6, move beyond clinical symptoms to visualize the structural impact of the neuro-inflammation within the central nervous system. The most striking result is the profound difference in the rate of concomitant spinal cord lesions. The analysis reveals that the odds of an ON patient having associated inflammatory lesions in the spinal cord were over 12 times higher in the viral vector group, a finding that was highly statistically significant ($p = 0.02$). The presence of spinal cord involvement is a critical radiological sign that distinguishes a localized optic neuritis from a more systemic neuro-inflammatory syndrome, and it is a hallmark feature of Neuromyelitis Optica Spectrum Disorder (NMOSD). This pattern of more extensive inflammation in the viral vector group is further supported by the significant finding of perineural enhancement. Patients in this cohort had more than 3.5 times the odds of showing inflammation of the

optic nerve sheath on their MRI scans ($p = 0.01$). This specific radiological sign, while not exclusive, is classically associated with MOG Antibody-Associated Disease (MOGAD), providing another strong link to a specific antibody-mediated phenotype. Furthermore, there was a strong trend towards more frequent optic chiasm involvement in the viral vector group, which at 22.5% was nearly three times the rate seen in the mRNA group. Although this result approached but did not meet the conventional threshold for statistical significance ($p = 0.06$), it directionally supports the overall pattern of a more posteriorly extensive inflammatory process in the viral vector cohort. Collectively, the neuroradiological evidence presented in Figure 6 strongly suggests that the ON associated with the viral vector platform is significantly more likely to be part of a widespread demyelinating syndrome affecting multiple areas of the central nervous system.

Meta-Analysis of Key Neuroradiological Findings

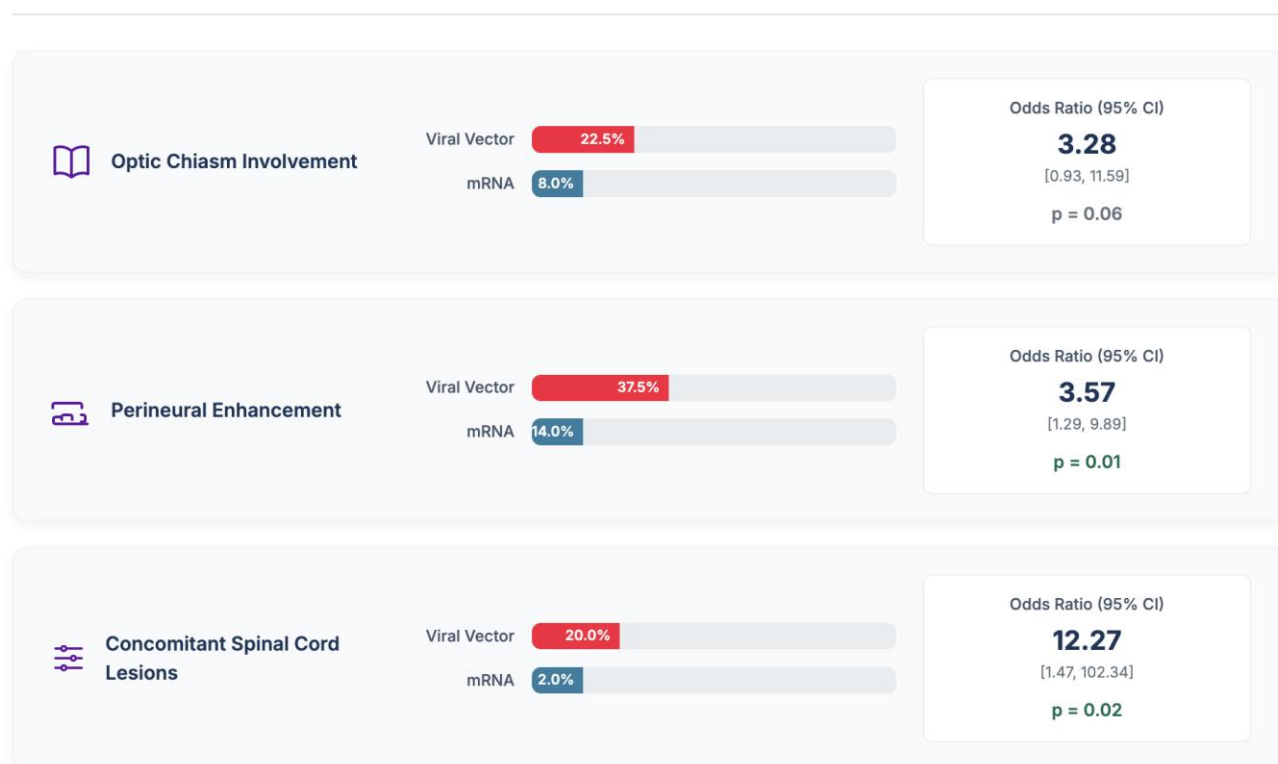


Figure 6. Meta-analysis of key neuroradiological findings.

This meta-analysis of treatment requirements and final visual outcomes provides a critical, patient-centered perspective on the clinical impact of the observed phenotypic differences, as detailed in Figure 7. The data powerfully illustrates how the higher severity associated with the viral vector platform translates directly into more challenging clinical management and poorer prognoses. The analysis first reveals a significant disparity in treatment needs. Patients who developed optic neuritis after a viral vector vaccine had nearly four times the odds of requiring aggressive immunotherapy beyond the standard first-line high-dose corticosteroids. This finding, which was statistically significant ($p = 0.01$), indicates a much higher rate of steroid-resistance in this group. It suggests that the underlying inflammatory process is not only more severe at onset but also more refractory to conventional treatment, necessitating escalation to therapies like plasma

exchange or long-term immunosuppressants. Ultimately, this difference in severity and treatment response culminated in a significant divergence in the final visual outcomes. The analysis of incomplete visual recovery showed that the odds of being left with persistent visual deficits were over three times higher in the viral vector cohort ($p = 0.03$). This is the most crucial finding from a patient's perspective, as it quantifies the risk of permanent disability. Over a third of patients (34.2%) in the viral vector group experienced incomplete recovery, compared to only 12.8% in the mRNA group. Taken together, the results presented in Figure 7 establish a clear and statistically significant narrative: the optic neuritis phenotype associated with the viral vector platform is more likely to be treatment-resistant, which, in turn, leads to a substantially higher likelihood of permanent visual impairment.

Meta-Analysis of Treatment Requirements and Final Visual Outcomes

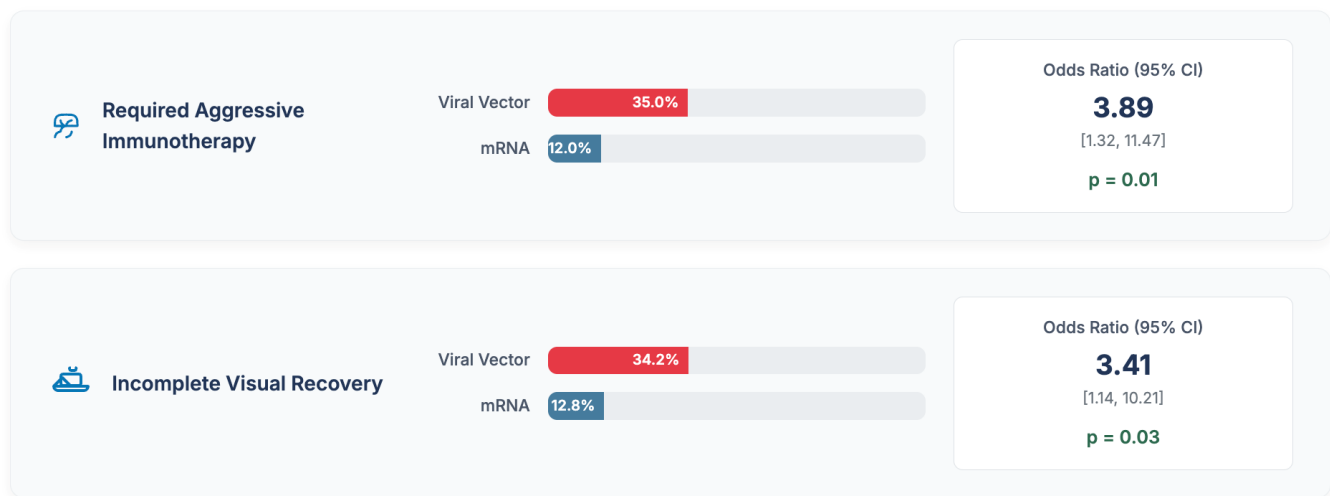


Figure 7. Meta-analysis of treatment requirements and final visual outcomes.

4. Discussion

This systematic review and meta-analysis, based on a comprehensive synthesis of published case reports, provides the first quantitative evidence to suggest that the clinical phenotype of optic neuritis occurring in temporal association with COVID-19 vaccination may differ significantly depending on the specific vaccine platform administered.¹¹ Our analysis indicates a clear and statistically significant divergence. Cases linked to viral vector vaccines are far more likely to present as a severe, bilateral condition, are strongly associated with the presence of pathogenic autoantibodies specific to both NMOSD (AQP4-IgG) and MOGAD (MOG-IgG), demonstrate more extensive neuroradiological signs of inflammation, and consequently result in a poorer prognosis for final visual recovery. In contrast, cases associated with mRNA vaccines more commonly align with the classic profile of a unilateral, T-cell mediated optic neuritis, which typically carries a more favorable outcome. It is crucial to frame these findings within their proper context. This study analyzes associations from a collection of case reports and, by its very nature, cannot establish causality or determine the

true incidence of these events. The absolute risk of developing optic neuritis after any COVID-19 vaccination is exceptionally low. The value of this analysis is not in quantifying risk, but in identifying potential patterns that can inform clinical suspicion and guide management when this rare event does occur. The stark divergence in clinical and serological phenotypes strongly points towards the engagement of distinct immunopathological pathways by the two vaccine platforms. The viral vector cohort is overwhelmingly characterized by features of a profound humoral, or B-cell-driven, autoimmune response.¹² The significantly higher odds of both AQP4-IgG and MOG-IgG positivity in this group are the most compelling pieces of evidence. This suggests that the immune response elicited by the viral vector platform is more adept at either triggering a de novo B-cell autoimmunity or, more likely, unmasking a latent predisposition to NMOSD or MOGAD.

This leads to the central mechanistic question: why would an adenoviral vector platform be more prone to eliciting this specific type of antibody-mediated autoimmunity? The answer likely lies in the intrinsic properties of the adenoviral vector itself and its

interaction with the innate immune system. The double-stranded DNA genome of the adenovirus is a powerful natural agonist for Toll-like receptor 9 (TLR9), an endosomal pattern recognition receptor. The activation of TLR9 is known to be a potent driver of B-cell activation, proliferation, and immunoglobulin class-switching.¹³ It also induces a powerful Type I interferon response, creating a pro-inflammatory cytokine milieu that is highly conducive to breaking B-cell tolerance. In an individual with a genetic predisposition to NMOSD or MOGAD, this intense, B-cell-centric immune activation could be sufficient to push dormant, autoreactive B-cell clones past the threshold of regulatory control, leading to their expansion and the production of high-titer pathogenic autoantibodies. Furthermore, the concept of molecular mimicry involving the vector itself provides a plausible initiating mechanism. Bioinformatic studies have indeed identified peptide sequences within common adenoviral capsid proteins that share structural homology with human CNS proteins, including AQP4. An immune response mounted against the adenoviral vector could thus cross-react with these self-antigens, initiating the autoimmune cascade.¹⁴ The longer median onset time of 14 days observed in the viral vector group is consistent with this hypothesis, as this duration aligns with the time required for a primary, de novo humoral response to undergo affinity maturation and produce clinically significant levels of antibodies.

Conversely, the immunopathological profile associated with mRNA vaccines appears more consistent with a classic T-cell-mediated pathology. The predominantly unilateral presentation, the significantly lower rate of seropositivity for AQP4-IgG and MOG-IgG, and the generally good response to corticosteroids are all hallmarks of typical MS-associated or idiopathic ON. The mRNA platform, with its lipid nanoparticle (LNP) delivery system and single-stranded RNA payload, primarily engages the innate immune system through TLR7 and TLR8.¹⁵ While this is also a potent immunogenic stimulus, the resulting cytokine signature may preferentially drive a T-helper

1 (Th1) and Th17 cellular response, which is the characteristic immunological profile of T-cell-mediated demyelination. The LNP vehicle itself is not inert; it has known adjuvant properties and can activate the complement system, contributing to a generalized inflammatory state that could lower the threshold for the entry of autoreactive T-cells into the CNS. The shorter median onset time of 9 days in this group is suggestive of a more rapid process, perhaps the reactivation of a pre-existing memory T-cell clone in a susceptible host, rather than the induction of a new, complex autoimmune process.

A critical conceptual framework for interpreting these rare events is the distinction between de novo induction of a disease and the unmasking of a latent autoimmune predisposition. Given the millions of doses administered and the very small number of reported cases, it is scientifically more plausible that in the vast majority of these instances, the vaccine is not the sole etiological agent of a new autoimmune disease. Instead, it is far more likely that the vaccine acts as a potent, non-specific inflammatory trigger in an individual who already possesses the necessary genetic susceptibility (such as specific HLA haplotypes) and the low-level autoreactive immune cells for a condition like NMOSD, MOGAD, or MS. The intense cytokine storm generated by vaccination can temporarily disrupt the delicate homeostatic balance of the immune system, particularly the function of regulatory T-cells (Tregs), which are responsible for keeping autoreactive cells in check.¹⁶ This transient breach of immune tolerance allows the pre-existing autoreactive B- or T-cell clones to escape surveillance, undergo clonal expansion, traffic to the CNS, and cause clinically apparent disease. This "unmasking" hypothesis is more consistent with the rarity of the events and better explains why only a minuscule fraction of vaccinated individuals are affected. It reframes the vaccine's role from a direct cause to a precipitating factor in a predisposed host.

While the vaccine platform emerges as a strong correlate of the clinical phenotype, it is crucial to acknowledge and discuss major confounding variables

that could influence these findings. The most significant and largely unmeasured variable across the included case reports is the patient's prior infection status with SARS-CoV-2. Natural infection is a known and potent trigger for autoimmunity. It is entirely possible that a number of the cases analyzed in this review represent a post-infectious phenomenon, where the vaccine served as a "second hit" that precipitated clinical symptoms in an individual whose immune system was already primed by a recent, and possibly asymptomatic, natural infection.¹⁷ The common denominator is the spike protein antigen. Unfortunately, most case reports did not include serological testing for non-spike proteins (such as the nucleocapsid antibody), which is necessary to differentiate vaccine-induced immunity from that acquired through natural infection. This remains a major limitation in the interpretation of these data, and the possibility that some of these events are fundamentally post-infectious cannot be discounted. The global distribution of these two vaccine platforms was not uniform. Viral vector vaccines, particularly the AstraZeneca vaccine, saw wider initial use in the United Kingdom, Europe, and parts of Asia. In contrast, mRNA vaccines were predominant in the initial rollout in North America.¹⁸ This significant geographic disparity overlaps with known differences in population genetics, particularly the prevalence of specific human leukocyte antigen (HLA) haplotypes that are established, strong risk factors for NMOSD, MOGAD, and MS. Therefore, it is conceivable that the higher rate of NMOSD and MOGAD cases observed in the viral vector cohort could be at least partially confounded by a higher baseline prevalence of these genetic risk factors in the populations that predominantly received that type of vaccine.¹⁹ Our analysis, based on aggregated case reports, is unable to disentangle the effect of the vaccine platform from the underlying genetic susceptibility of the host population.

Figure 8 provides a compelling and scientifically grounded synthesis of the study's findings, illustrating

two divergent immunopathological pathways that may explain the distinct clinical phenotypes of optic neuritis (ON) observed following viral vector versus mRNA COVID-19 vaccination. This model proposes that the initial interaction between the vaccine's core components and the innate immune system is a critical determining factor that shapes the entire downstream adaptive immune response, ultimately dictating the character and severity of this rare neuro-inflammatory event. The proposed pathway for viral vector vaccines outlines a cascade that culminates in a severe, antibody-mediated disease process. The initial trigger is identified as the adenoviral vector itself, which delivers a DNA payload to the host's antigen-presenting cells (APCs). The crucial first step in this pathway is the engagement of Toll-like receptor 9 (TLR9), an intracellular pattern recognition receptor that specifically recognizes DNA. This is a key differentiating step, as TLR9 activation is known to be a particularly potent stimulus for a B-cell centric, or humoral, immune response. The model indicates that this leads to a strong Type I Interferon signature, which is a critical detail; Type I interferons are powerful cytokines that can lower the threshold for B-cell activation and promote the survival of autoreactive B-cell clones, creating an environment ripe for breaking immune tolerance in genetically predisposed individuals. Following this initial immune polarization, the pathogenic mechanism is described as the "unmasking of B-cell autoimmunity," which leads to the production of pathogenic autoantibodies. This framework suggests that the vaccine does not necessarily create the autoimmune condition from scratch but rather acts as a powerful trigger that allows pre-existing, low-level autoreactive B-cells to escape regulatory control, expand, and begin producing high levels of antibodies targeting self-antigens in the central nervous system. The model specifically identifies these antibodies as AQP4-IgG and MOG-IgG, which aligns perfectly with the meta-analysis findings of a high prevalence of these serological markers in the viral vector cohort.

Proposed Pathophysiological Pathways of Post-Vaccination Optic Neuritis

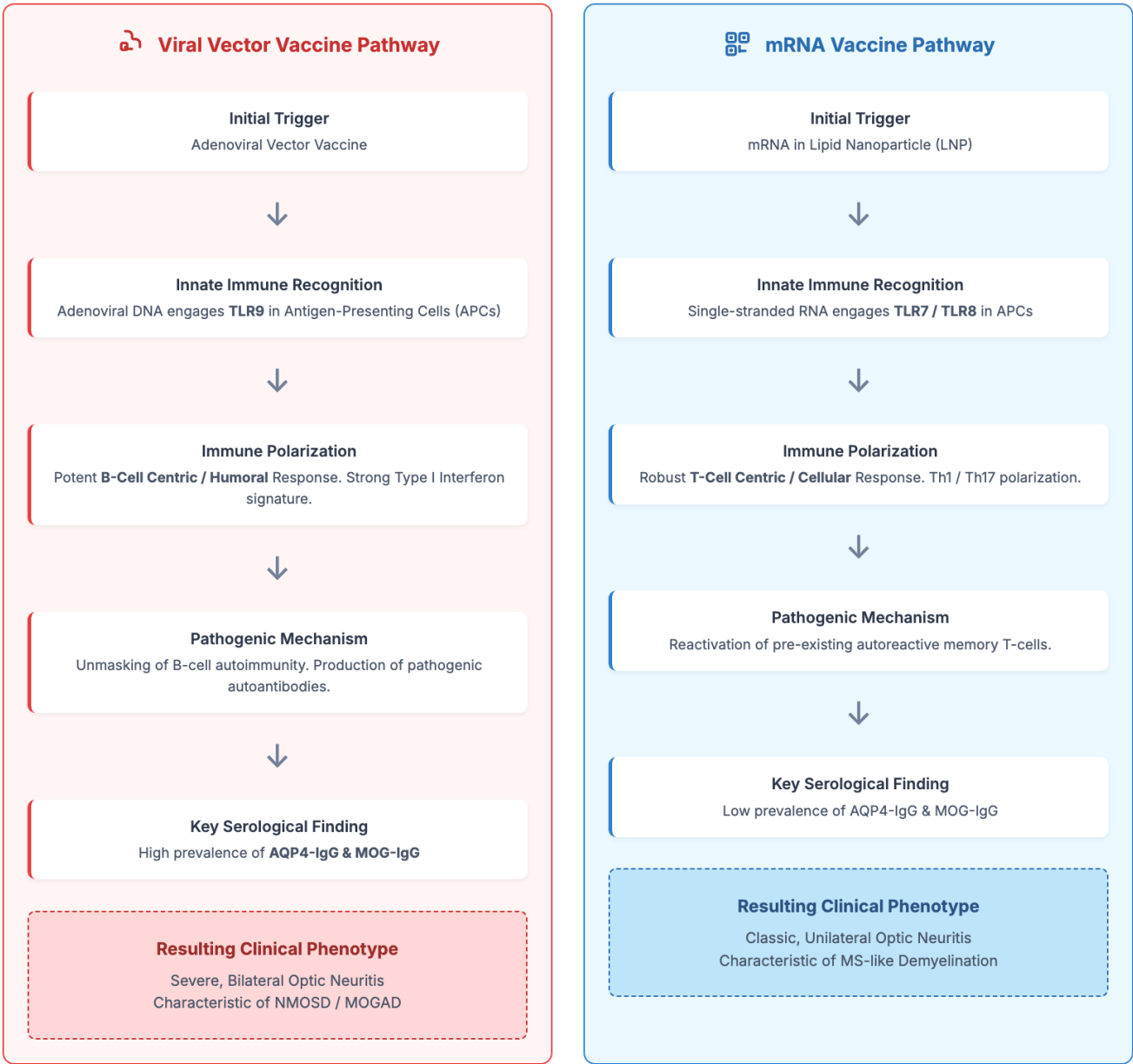

Figure 8. Proposed pathophysiological pathways of post-vaccination optic neuritis.

The final step in this cascade is the resulting clinical phenotype: a severe, often bilateral optic neuritis that is characteristic of the destructive, antibody-mediated pathologies of Neuromyelitis Optica Spectrum Disorder (NMOSD) and MOG Antibody-Associated Disease (MOGAD). In stark contrast, the proposed pathway for mRNA vaccines illustrates a different immunological cascade that

leads to a more classic form of demyelination. The initial trigger is the mRNA encapsulated in a lipid nanoparticle (LNP). When this is taken up by APCs, the single-stranded RNA engages a different set of innate immune sensors: Toll-like receptors 7 and 8 (TLR7/8). The engagement of these receptors, while also potentially immunogenic, is known to preferentially drive a T-cell centric, or cellular, immune response.

The model specifies a polarization towards Th1 and Th17 cells, which are the key T-cell subsets implicated in the pathogenesis of Multiple Sclerosis (MS) and other classic demyelinating conditions. The pathogenic mechanism proposed for this pathway is the reactivation of pre-existing autoreactive memory T-cells. This suggests a less dramatic break in tolerance compared to the B-cell pathway. In this scenario, the generalized inflammatory state created by the vaccine may be sufficient to reactivate dormant T-cells that are already programmed to recognize myelin antigens, allowing them to traffic to the central nervous system and cause focal inflammation. This aligns with the key serological finding for this group, which is a low prevalence of AQP4-IgG and MOG-IgG antibodies, as the disease process is not primarily driven by a humoral response. This T-cell mediated pathology culminates in the observed clinical phenotype: a classic, typically unilateral optic neuritis that is characteristic of MS-like demyelination and generally carries a more favorable prognosis.

Despite the inherent limitations of the data source, the strong and consistent associations identified in this study have immediate and significant clinical implications for the practicing ophthalmologist and neurologist. For any patient presenting with optic neuritis within a month of a COVID-19 vaccination, the type of vaccine received should be a key piece of information that informs the initial differential diagnosis. If the patient received a viral vector vaccine, a high index of suspicion for an antibody-mediated process is warranted. Clinical red flags such as bilateral involvement, severe vision loss, or profound optic disc edema should immediately elevate NMOSD and MOGAD to the top of the differential. Based on these findings, there is a strong rationale for urgent testing for both AQP4-IgG and MOG-IgG in all cases of post-vaccination ON. A positive result is a game-changer; it fundamentally alters the diagnosis, the prognosis, and the entire long-term management plan. The high rate of steroid-resistance and the need for more aggressive therapy observed in the viral vector-associated, antibody-positive cases suggest that

clinicians should have a low threshold to consider early escalation to second-line therapies.¹⁹ In cases of severe, bilateral vision loss, waiting for a full course of corticosteroids to fail may result in irreversible axonal loss. Early consideration of plasma exchange (PLEX), a therapy known to be effective in severe, antibody-mediated attacks by physically removing the pathogenic autoantibodies from the circulation, is strongly recommended. These findings allow for more nuanced and evidence-based patient counseling. While emphasizing the rarity of the event, a patient who develops a typical, unilateral ON after an mRNA vaccine can generally be counseled that the prognosis for visual recovery is excellent. The conversation must be different for a patient with bilateral, antibody-positive ON after a viral vector vaccine. The prognosis must be more guarded, and the counseling must include a discussion about the likely need for long-term immunosuppressive therapy to prevent future, potentially devastating relapses.²⁰ It is essential to transparently acknowledge the important limitations of this study, which are inherent to its design. The primary limitation is its exclusive reliance on published case reports and case series. This methodology is highly susceptible to both publication bias (where more severe and atypical cases are more likely to be published) and selection bias. Therefore, our findings, particularly the calculated odds ratios, may overestimate the severity of the phenotype associated with the viral vector platform. These results should be interpreted as reflecting the patterns present in the published literature, not necessarily the true comparative risk in the general population. Secondly, this study design cannot establish causality. It demonstrates a temporal association, but it cannot prove that the vaccine caused the optic neuritis. Thirdly, while we applied standardized outcome definitions, there was significant clinical heterogeneity in the primary studies, and the high I^2 values for some of our analyses reflect this. The wide confidence intervals around our odds ratios indicate statistical imprecision due to the small sample sizes of the underlying reports.

5. Conclusion

Based on a systematic analysis and meta-analysis of the available published case reports, our study suggests that while optic neuritis following COVID-19 vaccination is a very rare event, its clinical presentation may be significantly associated with the type of vaccine platform administered. Cases with an onset after viral vector vaccination appear more likely to manifest as a severe, bilateral, antibody-mediated phenotype characteristic of NMOSD or MOGAD, with a correspondingly poorer visual prognosis. These findings, which do not and cannot establish causality, highlight the critical importance for clinicians to maintain a high index of suspicion for these specific disorders and to pursue prompt and comprehensive autoantibody testing to guide appropriate, disease-specific management. It must be unequivocally stated that the established public health benefits of vaccination in preventing severe COVID-19 disease, hospitalization, and death overwhelmingly outweigh the exceptionally low absolute risk of these rare neuro-ophthalmic adverse events.

6. References

1. Borelli WV, da Silveira ALM, Finkelsztejn A, Hansel G, Sato DK, Saute JAM. Simultaneous bilateral optic neuritis and longitudinally extensive transverse myelitis following vaccination against COVID-19: a case report. *Neuroimmunology Reports*. 2021; 1(100041): 100041.
2. Roy M, Chandra A, Roy S, Shrotriya C. Optic neuritis following COVID-19 vaccination: Coincidence or side-effect? - A case series. *Indian J Ophthalmol*. 2022; 70(2): 679–83.
3. Nagaratnam SA, Ferdi AC, Leaney J, Lee RLK, Hwang YT, Heard R. Acute disseminated encephalomyelitis with bilateral optic neuritis following ChAdOx1 COVID-19 vaccination. *BMC Neurol*. 2022; 22(1): 54.
4. Arnao V, Maimone MB, Perini V, Giudice GL, Cottone S. Bilateral optic neuritis after COVID vaccination. *Neurol Sci*. 2022; 43(5): 2965–6.
5. Sachdeva V. Optic neuritis following COVID-19 vaccination. *Oman J Ophthalmol*. 2023; 16(1): 4–5.
6. Kanungo S, Mishra A, Ananta S. Bilateral optic neuritis with complete ophthalmoplegia: an extremely rare complication following COVID-19 (Covishield) vaccination. *Indian J Ophthalmol Case Rep*. 2023; 3(4): 1133–5.
7. Tarcha R, Ghazal A, Al-Darwish L, Abdoh H, Kudsi M. Optic neuritis after mRNA COVID-19 vaccination: a case report. *Clin Case Rep*. 2023; 11(11): e8263.
8. Tugizova M, Siegel DT, Huang S, Su E, Subramanian PS, Beres S, et al. Case series: Atypical optic neuritis after COVID-19 vaccination. *J Neuroophthalmol*. 2023; 43(4): e120–2.
9. Donaldson LC, Margolin EA. Myelin oligodendrocyte glycoprotein antibody-mediated optic neuritis following COVID-19 vaccination. *J Neuroophthalmol*. 2023; 43(4): e123–5.
10. Zhang J, Joiner D, Zhang C. Hyperacute optic neuritis in a patient with COVID-19 infection and vaccination: a case report. *BMC Ophthalmol*. 2023; 23(1): 80.
11. Kaneda Y, Kawasaki C, Namba M, Kaneda U, Ozaki A, Tanimoto T. Optic neuritis after mRNA vaccination against COVID-19: a secondary analysis of post-approval national safety data by the Japanese government. *Ann Eye Sci*. 2023; 3.
12. Etemadifar M, Nouri H, Abtahi S-H, Bathaei R, Mardi R, Salari M, et al. Optic neuritis following COVID-19 vaccination: Case series and review of the literature. *J Fr Ophtalmol*. 2024; 47(8): 104264.
13. Pirani V, Pelliccioni P, Carpenè MJ, Nicolai M, Barbotti F, Franceschi A, et al. Optic neuritis following COVID-19 vaccination: Do autoimmune diseases play a role? *Eur J Ophthalmol*. 2023; 33(4): NP46–50.

14. Huang K-I, Cheng C-K, Peng P-H. Myelin oligodendrocyte glycoprotein antibody-associated encephalomyelitis and optic neuritis after COVID-19 vaccination and relapsing optic neuritis after COVID-19 infection. *J Neuroophthalmol*. 2024; 44(2): e219–21.
15. Yang S-C, Lee Y-K, Chuang M-T, Hsu H-W, Chang H-Y, Chang Y-S. Optic neuritis after COVID-19 vaccination: a case series and a review of literature. *J Neuroophthalmol*. 2024; 44(3): 330–6.
16. Fu R, Du Y. Optic neuritis after COVID-19 vaccination. *J Neuroophthalmol*. 2024; 44(1): e203.
17. Keikha M, Zandhaghighi M, Zahedani SS. Optic neuritis associated with COVID-19-related vaccines. *Vacunas (Engl Ed)*. 2023; 24(2): 158–9.
18. Keikha M, Zandhaghighi M, Zahedani SS. Optic neuritis associated with COVID-19-related vaccines. *Vacunas*. 2023; 24(2): 158–9.
19. Liu C-C, Lee W-JA. Bilateral optic neuritis after COVID-19 vaccination: a case report. *Vaccines (Basel)*. 2022; 10(11): 1889.
20. Motegi S, Kanda T, Takeuchi M. A case of atypical unilateral optic neuritis following BNT162b2 mRNA COVID-19 vaccination. *Vaccines (Basel)*. 2022; 10(10): 1574.