



## Bioscientia Medicina: Journal of Biomedicine & Translational Research

Journal Homepage: [www.bioscmed.com](http://www.bioscmed.com)

### Beyond the Scar: A Case Report on the Clinical Presentation, Diagnostic Nuances, and Surgical Management of Type I Cesarean Scar Pregnancy

I Wayan Agus Surya Pradnyana<sup>1\*</sup>, Anak Agung Ngurah Jaya Kusuma<sup>2</sup>, Gde Bagus Rizky Kornia<sup>3</sup>

<sup>1</sup>Faculty of Medicine, Universitas Udayana/Prof. Dr. I.G.N.G Ngoerah General Hospital, Denpasar, Indonesia

<sup>2</sup>Maternal Fetal Medicine Division, Department of Obstetrics and Gynecology, Faculty of Medicine, Universitas Udayana/Prof. Dr. I.G.N.G Ngoerah General Hospital, Denpasar, Indonesia

<sup>3</sup>Department of Obstetrics and Gynecology, Faculty of Medicine, Universitas Udayana/Prof. Dr. I.G.N.G Ngoerah General Hospital, Denpasar, Indonesia

#### ARTICLE INFO

##### Keywords:

Cesarean scar pregnancy  
Ectopic pregnancy  
Laparotomy  
Type I CSP  
Ultrasonography

##### \*Corresponding author:

I Wayan Agus Surya Pradnyana

##### E-mail address:

[suryapradnyana@student.unud.ac.id](mailto:suryapradnyana@student.unud.ac.id)

All authors have reviewed and approved the final version of the manuscript.

<https://doi.org/10.37275/bsm.v9i7.1341>

#### ABSTRACT

**Background:** Cesarean scar pregnancy (CSP) is a rare form of ectopic pregnancy where the gestational sac implants within the fibrous tissue of a previous cesarean section scar. Its incidence is rising in parallel with increasing cesarean delivery rates, posing significant risks of maternal morbidity, including uterine rupture and severe hemorrhage. Type I CSP, or endogenous CSP, involves implantation on a healed scar with growth primarily towards the uterine cavity. Early and accurate diagnosis, relying heavily on ultrasonographic nuances, is crucial for appropriate management and fertility preservation. **Case presentation:** We present the case of a 36-year-old woman, G7P3033, with a history of two prior cesarean sections, who presented at 6-7 weeks of gestation with vaginal discharge. Transabdominal ultrasonography revealed a gestational sac implanted on the anterior uterine wall within the cesarean scar area, with a thin myometrium between the sac and the bladder, consistent with a Type I (endogenous, COS-1, Grade II) Cesarean Scar Pregnancy. The patient also had Stage II hypertension. After thorough evaluation and counseling, the patient underwent a laparotomy with wedge resection of the CSP and scar revision, along with bilateral fimbriectomy as per her request for sterilization. **Conclusion:** This case highlights the importance of high clinical suspicion for CSP in pregnant women with previous cesarean sections presenting with early pregnancy symptoms. Detailed ultrasonography is paramount for accurate diagnosis, classification, and guiding management. Surgical management, specifically laparotomy with wedge resection and scar repair, proved to be an effective treatment for this Type I CSP, allowing for removal of the ectopic pregnancy and reinforcement of the uterine wall, while addressing the patient's desire for permanent contraception. Timely intervention is key to preventing life-threatening complications and preserving future reproductive options if desired.

#### 1. Introduction

Cesarean scar pregnancy (CSP) represents one of the rarest forms of ectopic gestation, yet it is increasingly encountered in clinical practice due to the global rise in cesarean delivery rates. Estimated to occur in approximately 1 in 1800 to 1 in 2500 pregnancies among women with a history of at least one cesarean section, CSP accounts for about 6% of all

ectopic pregnancies in this demographic. It is defined by the implantation of the gestational sac within the fibrous tissue of a myometrial defect at the site of a prior uterine incision, most commonly a cesarean section scar. This aberrant implantation site predisposes to severe, life-threatening complications, including uterine rupture, catastrophic hemorrhage, placenta accreta spectrum (PAS) disorders if the

pregnancy progresses, and the potential need for emergency hysterectomy, leading to loss of fertility and significant maternal morbidity, and in rare cases, mortality.<sup>1,2</sup>

The pathophysiology of CSP is thought to involve the invasion of trophoblastic tissue into a microscopic dehiscence tract or a poorly healed area within the cesarean scar. Several factors may contribute to the formation of such a scar defect or "niche," including the specific surgical technique used for uterine closure (single versus double layer, locking versus unlocking sutures), the number of previous cesarean sections, a short interpregnancy interval, incomplete healing, and the presence of adhesions or a retroverted uterus. Studies have demonstrated that myometrial thinning at the scar site is more pronounced with an increasing number of previous cesarean sections, thereby elevating the risk of CSP. Low oxygen tension within the scar tissue has also been postulated as a factor that might attract the implanting blastocyst.<sup>3,4</sup>

CSP is broadly classified into two main types based on the depth of implantation and direction of growth, which have implications for prognosis and management. Type I CSP, also referred to as endogenic or "on-the-scar" pregnancy, occurs when the gestational sac implants on a relatively well-healed scar and grows predominantly towards the uterine cavity or cervico-isthmic space. These pregnancies may sometimes progress, but still carry a significant risk of complications. Type II CSP, or exogenic "in-the-niche" pregnancy, involves deep implantation into a dehiscence scar with growth towards the myometrium, serosa, and potentially into the bladder or abdominal cavity. Type II CSPs are associated with a higher risk of early uterine rupture and severe hemorrhage. The case presented in this report is a Type I CSP. Further classifications, such as the one proposed by Fu et al., consider gestational sac location, diameter, and myometrial thickness to stratify risk and guide treatment.<sup>5,6</sup>

The clinical presentation of CSP is often nonspecific and can be insidious. While some patients may experience painless vaginal bleeding or mild lower

abdominal pain, a significant proportion (up to 37-40%) may be asymptomatic in the first trimester, with the diagnosis being made incidentally during routine obstetric ultrasonography. This variability makes early diagnosis challenging and reliant on a high index of suspicion, especially in women with a history of cesarean delivery.<sup>7,8</sup>

The optimal management of CSP is still debated and depends on various factors, including the type and location of CSP, gestational age, fetal viability, hemodynamic stability of the patient, desire for future fertility, and available expertise and resources. Options range from expectant management (rarely chosen due to high risks), medical management (systemic or local methotrexate), to various surgical interventions. Surgical approaches include dilation and curettage (D&C, often associated with a high risk of hemorrhage if not carefully selected), hysteroscopic resection, transvaginal resection, laparoscopic resection, and laparotomy with wedge resection of the CSP and scar repair. Uterine Artery Embolization (UAE) may be used as an adjunct to reduce bleeding with other procedures. Surgical management, particularly approaches that involve excision of the scar tissue and repair, offers the advantage of removing the ectopic pregnancy, repairing the uterine defect, and potentially reducing the risk of recurrence.<sup>9,10</sup>

This case report contributes to the existing literature by presenting a detailed account of a Type I cesarean scar pregnancy (CSP) in a patient with a high-parity obstetric history and multiple previous cesarean sections, a demographic at notably increased risk. The novelty lies in the comprehensive exploration of the diagnostic journey, emphasizing the practical application of specific ultrasonographic nuances (including COS-1 classification and Grade II assessment) that were pivotal in accurate diagnosis and subsequent tailored surgical planning. Furthermore, this report underscores the successful application of laparotomy with wedge resection and meticulous scar reconstruction, not only as a definitive treatment for the CSP but also seamlessly integrated

with the patient's request for permanent sterilization (bilateral fimbriectomy), a combined surgical approach less commonly detailed in CSP literature. The careful management of concomitant Stage II hypertension throughout the perioperative period also adds a layer of practical clinical insight. By documenting this multifaceted case, we provide valuable insights into managing complex presentations of a rare condition, reinforcing the efficacy of traditional open surgical approaches when indicated or preferred. The primary aim of this case report is to meticulously describe the clinical presentation, diagnostic pathway, highlighting key ultrasonographic markers, and the successful surgical management of a Type I cesarean scar pregnancy in a patient with multiple risk factors.

## 2. Case Presentation

The patient was a 36-year-old Indonesian woman, residing in Tabanan, Bali, who presented with a complex obstetric history and a current, concerning early pregnancy. She was employed in the private sector, as was her husband. Her physical stature was recorded with a height of 149 cm and a pre-pregnancy weight of 66 kg, yielding a body mass index (BMI) of 29.7 kg/m<sup>2</sup>. This BMI categorizes her as overweight, a factor that, while not a direct cause, is often considered in the overall assessment of obstetric patients due to potential associations with various pregnancy-related complications and surgical considerations. She had been married twice, with obstetric events occurring during both unions. The patient was referred to the specialist clinic by her primary obstetrician-gynecologist with a suspected diagnosis of cesarean scar pregnancy (CSP). Her chief complaint upon presentation was a one-week history of minimal vaginal discharge. She described the discharge as non-foul smelling and reported no associated significant abdominal pain, cramping, or overt vaginal bleeding, which are often alarming symptoms in early pregnancy complications. The suspicion of CSP had arisen during a routine prenatal examination conducted when she was approximately 5 to 6 weeks into her gestation. Her menstrual history

was notable for menarche at the age of 13, followed by regular 28-day menstrual cycles, each lasting approximately 7 days with a self-reported normal flow volume of around 60 cc. She had a history of using injectable contraceptive agents, but these had been discontinued in 2012. The patient was unable to recall the exact date of her last menstrual period (LMP) with certainty, a common occurrence that necessitates reliance on early ultrasonography for accurate gestational dating. Based on initial assessments and an early ultrasound by the referring physician (which showed a crown-rump length (CRL) corresponding to 7 weeks and 1 day), her estimated date of delivery was projected to be November 27<sup>th</sup>, 2024. At the time of her detailed evaluation at our institution on April 15<sup>th</sup>, 2024, her gestational age was confirmed by ultrasound to be 7 weeks and 5 days. Prior to this referral, she had received antenatal care (ANC) on three occasions from an obstetrician-gynecologist for the current pregnancy.

The patient's obstetric history was extensive and particularly significant, marking her current pregnancy as her seventh (Gravida 7). She had achieved three live births (Para 3) and experienced three prior first-trimester pregnancy losses (Abortions/Miscarriages 3), denoted as G7P3033. Her first pregnancy (G1) resulted in a spontaneous vaginal delivery of a live female infant at term, with a birth weight of 2100 grams. Her second pregnancy (G2) in 2012 ended in a first-trimester abortion, which was managed with a dilatation and curettage (D&C) procedure. Her third pregnancy (G3) in 2018, during her second marriage, also resulted in a first-trimester abortion; however, no curettage was performed on this occasion. Her fourth pregnancy (G4) in 2019 progressed to term, culminating in the delivery of a live female infant weighing 3200 grams. This delivery was via her first cesarean section, indicated due to premature rupture of membranes (PROM). Her fifth pregnancy (G5) in 2021 was diagnosed as a blighted ovum, for which a D&C procedure was performed. Her sixth pregnancy (G6) in 2022 also resulted in a term delivery of a live female infant,

weighing 3300 grams. This delivery was via her second cesarean section; the specific indication for this repeat cesarean section was noted as Locus Minoris Resistitiae (LMR), implying a uterine scar from the previous operation. Her seventh pregnancy (G7) was the current gestation under investigation. This history of two prior cesarean sections, particularly the most recent one in 2022, placed her at a significantly elevated risk for complications such as CSP and placenta accreta spectrum disorders. Her history of multiple D&C procedures was also noted, as uterine instrumentation, while necessary, can sometimes contribute to endometrial changes or scarring. Regarding her past medical and surgical history, aside from the two cesarean sections and two D&C procedures detailed above, she denied any other significant illnesses or surgeries. However, during the current evaluation, she was diagnosed with Stage II Hypertension, with a presenting blood pressure of 130/80 mmHg. She denied any known allergies to medications or food and was not on any regular medications prior to the recent diagnosis of hypertension, for which Amlodipine 5mg daily had been initiated by the referring physician. A plan was made in consultation with cardiology to switch this to Ramipril 5mg daily post-operatively. Her family history of disease was not known by the patient.

The patient was in good general condition, appeared alert, cooperative, and was fully conscious, with a Glasgow Coma Scale (GCS) score of 15/15 (Eye response E4, Verbal response V5, Motor response M6). Her vital signs were recorded as follows: blood pressure was 130/80 mmHg, confirming her hypertensive status; pulse rate was 84 beats per minute, regular in rhythm and normal in volume; respiratory rate was 18 breaths per minute, unlabored; and her axillary temperature was 36.4°C, indicating she was afebrile. A systemic examination was performed. The Head, Eyes, Ears, Nose, and Throat (HEENT) examination revealed a normocephalic and atraumatic head. Her sclerae were anicteric, and conjunctivae were pink, suggesting no significant anemia or jaundice. There was no nasal

discharge, and the oropharynx appeared clear. No cervical lymphadenopathy was palpated. Cardiovascular system examination revealed distinct S1 and S2 heart sounds with a regular rhythm; no murmurs, rubs, or gallops were appreciated. Peripheral pulses were palpable, strong, and equal bilaterally. Respiratory system examination indicated a clear chest to auscultation bilaterally, with good air entry and no adventitious sounds such as wheezes, rales, or rhonchi. The abdominal examination revealed a soft and non-tender abdomen. The uterine fundus was palpable approximately midway between the symphysis pubis and the umbilicus, which was consistent with an early pregnancy but also required careful interpretation in the context of a suspected scar implantation. There was no palpable organomegaly or distinct masses. Bowel sounds were present and normal in character. There was no abdominal distension noted. An obstetric pelvic examination, including a sterile speculum and bimanual assessment, was conducted as part of the pre-operative reassessment on April 17<sup>th</sup>, 2024. The external genitalia appeared normal. The speculum examination revealed no active bleeding or significant discharge from the cervical os at that time. The cervix appeared visually healthy, firm, and closed. On bimanual examination, the uterus was found to be anteverted, slightly enlarged to a size consistent with the estimated gestational age, and was non-tender on palpation. The adnexal regions were palpated and found to be non-tender, with no adnexal masses appreciated.

Several laboratory investigations were conducted. Her baseline complete blood count (CBC) showed: Hemoglobin: 12.8 g/dL; Hematocrit: 38.0%; White Blood Cell Count (WBC): 7.5 x10<sup>3</sup>/L; and Platelet Count: 295 x10<sup>3</sup>/L, indicating no significant anemia, infection, or thrombocytopenia prior to surgery. Her initial serum  $\beta$ -human Chorionic Gonadotropin ( $\beta$ -hCG) level was 28,500 mIU/mL. This quantitative assessment helped confirm pregnancy viability alongside ultrasound findings and served as a crucial baseline for postoperative follow-up. Her blood type

was O Positive. The preoperative coagulation profile (Prothrombin Time (PT): 12.5 seconds; International Normalized Ratio (INR): 1.0; activated Partial Thromboplastin Time (aPTT): 30 seconds) was normal, ruling out any bleeding diathesis. Given her hypertension, baseline renal function tests (Blood Urea Nitrogen (BUN): 12 mg/dL; Creatinine: 0.7 mg/dL) and liver function tests (Aspartate Aminotransferase (AST): 20 U/L; Alanine Aminotransferase (ALT): 18 U/L; Total Bilirubin: 0.5 mg/dL) were within normal limits. A routine preoperative urine analysis showed: yellow, clear appearance; pH 6.0; Specific Gravity 1.015; Protein: Nil; Glucose: Nil; Ketones: Nil; Leukocytes: Trace; and Blood: Nil. A preoperative chest X-ray was performed and revealed clear lung fields with no evidence of active cardiopulmonary disease, confirming her fitness for general anesthesia. Postoperatively, a CBC was performed six hours after the surgery, which revealed: WBC  $14.31 \times 10^3/\text{L}$  (a mild leukocytosis, common post-surgery due to inflammatory response), Hemoglobin 12.60 g/dL, Hematocrit 37.40%, and Platelet count  $289 \times 10^3/\text{L}$ . These results were reassuring, indicating no significant intraoperative or immediate postoperative hemorrhage and stable hematological parameters.

Diagnostic imaging, particularly ultrasonography, was pivotal in establishing the diagnosis. A transabdominal sonography (TAS) (Figure 1) provided the initial definitive evidence. The superior portion of the uterine cavity and the endocervical canal were visualized and confirmed to be empty, a crucial criterion for differentiating CSP from a normally sited low intrauterine pregnancy or a cervical pregnancy. A single, well-defined gestational sac was identified. Its location was highly specific: implanted directly on the anterior wall of the lower uterine segment, precisely within the area corresponding to the scar from her previous cesarean sections. The crown-rump length (CRL) of the embryo within the sac corresponded to a gestational age of 7 weeks and 5 days. Fetal cardiac activity was present, indicating a live scar ectopic pregnancy at the time of this definitive scan. A critical

and defining feature observed was the condition of the myometrium overlying the gestational sac. It was described as markedly thin. This attenuation of the myometrial layer between the gestational sac and the urinary bladder is a hallmark of CSP, signifying that the implantation has occurred within the scar defect, compromising the uterine wall integrity at that site. The myometrial thickness was estimated to be less than 2-3 mm. Both the right and left adnexa (ovaries and fallopian tubes) were visualized and reported as appearing normal, with no adnexal masses or signs of ectopic pregnancy elsewhere. There was no free fluid observed in the pouch of Douglas (cul-de-sac), the absence of which suggested no current intraperitoneal bleeding or rupture. Color Doppler imaging revealed prominent peritrophoblastic vascularity surrounding the gestational sac at the site of implantation within the scar. This increased vascular flow confirmed active trophoblastic invasion. The peri-trophoblastic perfusion remained intense throughout the observation period. The sonographic findings were consistent with a COS-1. This sign, assessed on a sagittal view, describes the relationship of the gestational sac to an imaginary line drawn from the internal cervical os to the uterine fundus through the endometrium (the endometrial line). In COS-1, indicative of a Type I (endogenic) CSP, the majority (more than two-thirds) of the sac's superior-inferior diameter is located above this endometrial line, signifying that the primary growth vector of the pregnancy is towards the uterine cavity. The patient was diagnosed as: Gravida 7, Para 3, with a current gestation of 7 weeks and 5 days, complicated by a Type I (Endogenic, COS-1) Cesarean Scar Pregnancy, Grade II, located at the site of Locus Minoris Resistentiae (LMR) from her two former cesarean sections. Concurrently, she was diagnosed with Stage II Hypertension (Table 1).

The pre-operative phase was crucial for optimizing the patient's condition and ensuring a shared understanding of the impending procedure. Extensive counseling was provided to the patient and her husband regarding the nature of CSP, the significant

risks associated with it (including the potential for life-threatening hemorrhage, uterine rupture, and the possible need for emergency hysterectomy), the proposed surgical intervention, alternative management options (though less suitable in her specific context given the live CSP and desire for sterilization), and the expected prognosis. Informed written consent was diligently obtained for the planned procedures: a laparotomy, wedge resection of the Cesarean Scar Pregnancy, meticulous uterine scar repair, and bilateral fimbriectomy for permanent contraception. Given her newly diagnosed Stage II Hypertension, a cardiology consultation was sought. The cardiologist reviewed her case and recommended continuation of her Amlodipine pre-operatively, with a plan to switch to Ramipril 5mg daily post-operatively for long-term management. A pre-anesthesia consultation was also conducted to assess her fitness for surgery and plan the anesthetic approach. All preoperative investigations, including her complete blood count, coagulation profile, renal and liver function tests, urine analysis, and chest X-ray, were reviewed and found to be within acceptable limits, indicating her general fitness for the planned major surgery. Her blood group was confirmed as O Positive. On the day of surgery, April 17, 2024, the patient was kept NPO (Nil Per Os) for at least eight hours prior to the procedure to minimize aspiration risk. Prophylactic intravenous antibiotics, specifically Cefazolin 2 grams, were administered approximately 30 to 60 minutes prior to the skin incision to reduce the risk of surgical site infection. The abdominal skin was prepared using an appropriate antiseptic solution. The patient was then transferred to the operating theatre, where general anesthesia with endotracheal intubation was skillfully administered by the anesthesia team. Standard American Society of Anesthesiologists (ASA) monitoring was initiated and maintained throughout the procedure, including electrocardiogram (ECG), non-invasive blood pressure (NIBP), peripheral oxygen saturation (SpO<sub>2</sub>), end-tidal carbon dioxide (EtCO<sub>2</sub>), and core body temperature.

The surgical intervention was performed with a multidisciplinary team approach. The primary procedures undertaken were a laparotomy, followed by wedge resection of the Cesarean Scar Pregnancy, comprehensive uterine scar repair, and bilateral fimbriectomy (Figure 2). A Pfannenstiel skin incision was made, and the abdominal layers (subcutaneous tissue, rectus fascia, rectus muscles) were sequentially opened to gain access to the peritoneal cavity. Upon entering the abdomen, the uterus and other pelvic organs were carefully exposed and assessed. The uterus was found to be gravid, consistent with a 7-8 week gestation. The cesarean scar pregnancy was readily visualized as a distinct, bluish, and vascular bulge, measuring approximately 3-4 cm in diameter, located on the anterior surface of the lower uterine segment precisely at the site of the previous cesarean section scars. Minimal adhesions were noted in the vesicouterine space, which were carefully lysed to improve exposure. To manage the CSP, sutures were placed lateral to the identified bulge to aid in traction and minimize bleeding. A careful circumferential incision was then made around the CSP bulge, extending through the thinned myometrium and into the underlying scar tissue. This allowed for the *en bloc* excision of the gestational sac and the surrounding compromised scar tissue, performing a wedge resection. Within the excised segment, the products of conception, including the gestational sac and embryonic tissue consistent with a 7-8 week gestation, were clearly identified. Following the complete removal of the CSP and the associated scar tissue, the resultant uterine defect, approximately 3 cm in length, was meticulously repaired. The repair was performed in two layers to ensure optimal anatomical reconstruction and hemostasis. The first layer involved approximating the myometrium using a continuous locking 1-0 absorbable polyglactin suture. The second layer closed the seromuscular defect and the uterine serosa with interrupted, imbricating 2-0 absorbable polyglactin sutures. This layered closure aimed to restore the integrity of the uterine wall at the site of the previous defect (Table 2).

Table 1. Summary of patient's clinical findings.

Category	Parameter	Finding
Demographics	Age	36 years
	Gravidity/Parity	Gravida 7, Para 3, Abortions/Miscarriages 3 (G7P3033)
	Last Cesarean Section	2022 (second CS), 2019 (first CS)
	Marital Status	Married (second marriage)
	Occupation	Employed in the private sector (husband also in the private sector)
	Residence	Tabanan, Bali, Indonesia
	Height	149 cm
	Weight (pre-pregnancy)	66 kg
	Body Mass Index (BMI)	29.7 kg/m <sup>2</sup> (Overweight)
Anamnesis	Chief Complaint	Vaginal discharge for one week
	History of Present Illness	Minimal, non-foul smelling vaginal discharge; no associated abdominal pain or heavy bleeding. Suspected CSP at 5-6 weeks of gestation during a routine prenatal examination by a referring obstetrician.
	Last Menstrual Period (LMP)	Patient unable to recall accurately
	Estimated Gestational Age (EGA)	Initially 6-7 weeks; confirmed as 7 weeks 5 days by ultrasound on April 15 <sup>th</sup> , 2024.
	Antenatal Care (ANC)	Received ANC three times from an obstetrician-gynecologist prior to referral.
	Obstetric History Summary	G1: Spontaneous vaginal delivery, term, female, 2100g. G2: Abortion (2012), D&C. G3: Abortion (2018), no D&C. G4: Cesarean section (PRO), term, female, 3200g (2019). G5: Blighted ovum (2021), D&C. G6: Cesarean section, term, female, 3300g (2022). G7: Current pregnancy.
	Menstrual History	Menarche at 13 years; regular 28-day cycle; duration 7 days; volume approx. 60 cc.
	Contraceptive History	Previously used injectable contraceptive agents; discontinued since 2012.
	Past Medical History	History of two cesarean sections. Recently diagnosed with Stage II Hypertension. Denied other chronic illnesses.
	Past Surgical History	Cesarean section (2019), Cesarean section (2022), Dilatation and Curettage (2012 for abortion), Dilatation and Curettage (2021 for blighted ovum).
	Family History of Disease	Not known by the patient.
	Allergies	Denied any known allergies to medications or food.
	Current Medications	Amlodipine 5mg for hypertension (to be switched to Ramipril 5mg post-op).
Physical examination	General Condition	Good, alert, cooperative, fully conscious.
	Vital Signs	Blood Pressure: 130/80 mmHg; Pulse: 84 beats/minute (regular); Respiratory Rate: 18 breaths/minute; Axillary Temperature: 36.4°C.
	Glasgow Coma Scale (GCS)	15/15 (E4V5M6)
	HEENT	Normocephalic, atraumatic. Anicteric sclera, pink conjunctivae. No nasal discharge, oropharynx clear. No cervical lymphadenopathy.
	Cardiovascular	S1, S2 distinct, regular rhythm, no murmurs, rubs, or gallops. Peripheral pulses palpable and equal.
	Respiratory	Chest clear to auscultation bilaterally, no wheezes, rales, or rhonchi. Good air entry.
	Abdomen	Soft, non-tender. Fundus uteri palpable approximately midway between the symphysis pubis and the umbilicus. Bowel sounds normal. No organomegaly or masses. No distension.
	Obstetric (Pelvic) Examination	External genitalia normal. Vaginal examination (pre-op reassessment): No active bleeding or significant discharge observed from the cervical os. Cervix appeared closed, firm. Uterus consistent with early pregnancy size on bimanual palpation, non-tender. Adnexa non-tender, no masses.
Laboratory findings	Preoperative Complete Blood Count (CBC)	Hemoglobin: 12.8 g/dL; Hematocrit: 38.0%; White Blood Cell Count (WBC): 7.5 x10 <sup>3</sup> /L; Platelet Count: 295 x10 <sup>3</sup> /L.
	Postoperative CBC (6 hours)	WBC: 14.31 x10 <sup>3</sup> /L; Hemoglobin: 12.60 g/dL; Hematocrit: 37.40%; Platelets: 289 x10 <sup>3</sup> /L.
	Serum β-hCG (initial)	28,500 mIU/mL
	Blood Type & Rh Factor	O Positive
	Coagulation Profile (Pre-op)	PT: 12.5 sec; INR: 1.0; aPTT: 30 sec.
	Renal & Liver Function (Pre-op)	BUN: 12 mg/dL; Creatinine: 0.7 mg/dL; AST: 20 U/L; ALT: 18 U/L; Total Bilirubin: 0.5 mg/dL.
	Urine Analysis (Pre-op)	Yellow, clear; pH 6.0; Specific Gravity 1.015; Protein: Nil; Glucose: Nil; Ketones: Nil; Leukocytes: Trace; Blood: Nil.
Imaging findings	Transabdominal Sonography (TAS)	
	Uterine Cavity/Endocervical Canal	Empty superior uterine cavity and endocervical canal.
	Gestational Sac (GS)	Single live intrauterine (within scar) gestational sac located in the anterior wall of the lower uterine segment, within the previous cesarean scar defect. CRL consistent with 7 weeks 5 days gestation. Fetal cardiac activity present.
	Myometrium	Markedly thin myometrial layer (estimated <2-3 mm) between the gestational sac and the urinary bladder.
	Adnexa	Bilateral adnexa appeared normal.
	Free Fluid (Cul-de-sac)	No free fluid observed.
	Color Doppler	Evidence of prominent peritrophoblastic vascularity around the gestational sac at the implantation site within the scar.
	Cross-Over Sign (COS)	Consistent with COS-1 (majority of GS superior-inferior diameter above the endometrial line, growing towards the uterine cavity).
	Chest X-ray (Pre-op)	Clear lung fields, no active cardiopulmonary disease.
Clinical diagnosis	Primary Diagnosis	G7P3033 at 7 weeks 5 days with Type I (Endogenic, COS-1) Cesarean Scar Pregnancy, Grade II.
	Comorbidities	Stage II Hypertension.
	Other	Locus Minoris Resistentiae (LMR) due to two previous cesarean sections.

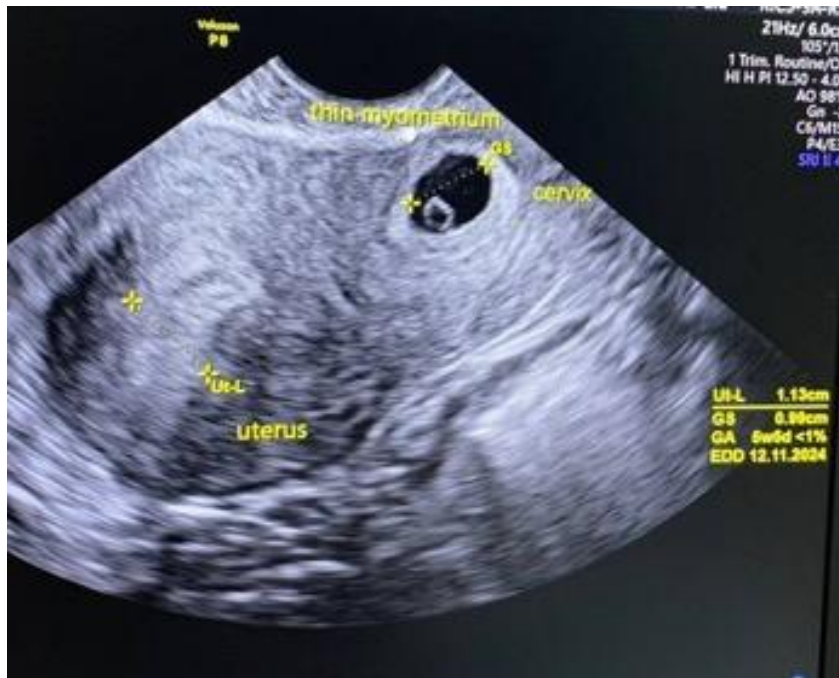

Figure 1. Transabdominal sonography results. The ultrasound revealed there is a gestational sac that was implanted into the thin myometrium, which was the scar of a previous pregnancy.

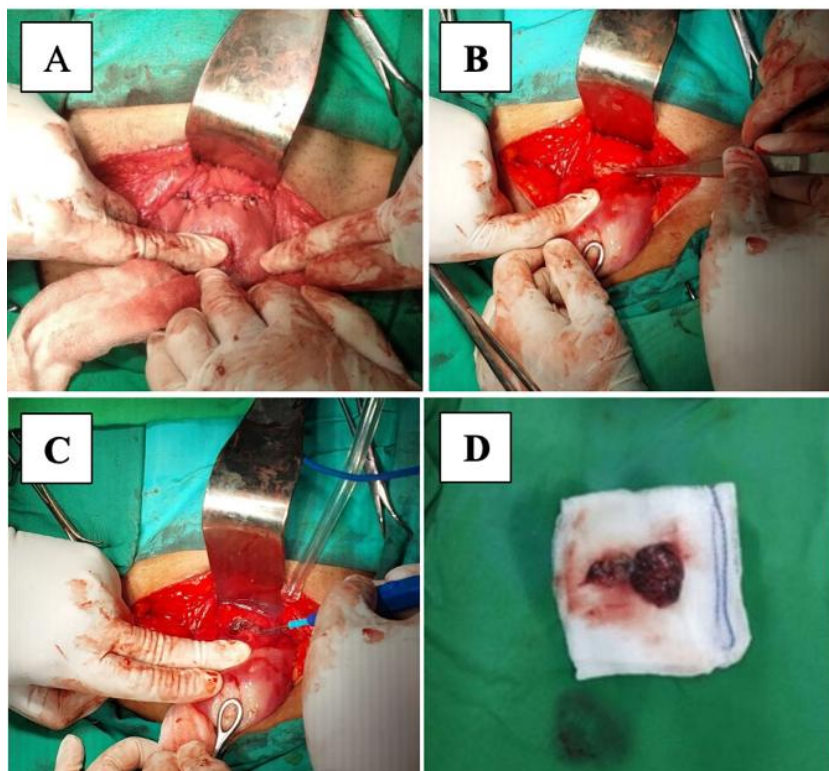


Figure 2. Durante of surgery. (A) Incision through the abdomen into the uterus revealed the cesarean scar, (B) Incision through the cesarean scar was done, (C) The product of conception was seen during the incision, (D) The product of conception was excised.



Table 2. Summary of treatment procedure and follow-up.

Category	Parameter	Details
Pre-operative preparation	Patient Counseling & Consent	Extensive counseling regarding diagnosis of Type I CSP, associated risks (uterine rupture, hemorrhage, hysterectomy), management options, and prognosis. Informed written consent obtained for laparotomy, wedge resection of CSP, uterine scar repair, and bilateral fimbriectomy.
	Pre-operative Consultations	Cardiology consultation for Stage II Hypertension; recommendation to switch Amlodipine to Ramipril post-operatively. Anesthesia consultation for fitness assessment.
	Investigations Review	Review of preoperative CBC, coagulation profile, renal and liver function tests, urine analysis, and chest X-ray (all within acceptable limits for surgery). Blood group O Positive confirmed.
	Fasting	NPO (Nil Per Os) for 8 hours prior to surgery.
	Prophylactic Antibiotics	Intravenous Cefazolin 2g administered 30-60 minutes prior to skin incision.
	Skin Preparation	Abdominal skin preparation with antiseptic solution.
	Anesthesia	General anesthesia with endotracheal intubation. Standard ASA monitoring initiated (ECG, NIBP, SpO <sub>2</sub> , EtCO <sub>2</sub> , Temperature).
Surgical procedure	Date of Surgery	April 17 <sup>th</sup> , 2024
	Primary Procedures Performed	Laparotomy, Wedge Resection of Cesarean Scar Pregnancy, Uterine Scar Repair, Bilateral Fimbriectomy
	Laparotomy	Pfannenstiel skin incision. Abdominal layers opened sequentially to access the peritoneal cavity. Uterus and pelvic organs exposed.
	Identification & Isolation of CSP	Uterus identified; CSP visualized as a bluish, vascular bulge approximately 3-4 cm in diameter on the anterior surface of the lower uterine segment at the site of the previous cesarean scar. Minimal adhesions noted in the vesicouterine space.
	Wedge Resection of CSP	Stay sutures placed lateral to the CSP. Careful circumferential incision made around the CSP bulge, extending through the myometrium into the scar tissue. The gestational sac and surrounding scar tissue containing trophoblastic elements were excised <i>en bloc</i> (wedge resection).
	Removal of Products of Conception	The products of conception, including the gestational sac and fetal tissue (approx. 7-8 weeks size), were identified within the excised segment.
	Uterine Scar Repair	The uterine defect resulting from the wedge resection (approx. 3 cm in length) was repaired meticulously in two layers: First layer with continuous locking 1-0 absorbable polyglactin suture approximating the myometrium; Second layer with interrupted imbricating 2-0 absorbable polyglactin suture for the seromuscular layer and serosa, ensuring good hemostasis and anatomical reconstruction.
	Bilateral Fimbriectomy	Both fallopian tubes identified. Fimbriated ends grasped, and fimbriectomy performed bilaterally using ligation and excision technique for permanent sterilization as per patient's request.
	Hemostasis & Peritoneal Lavage	Meticulous hemostasis ensured throughout the procedure. Pelvic cavity irrigated with warm normal saline and suctioned clear.
	Closure	Abdominal wall closed in layers (peritoneum, fascia, subcutaneous tissue, skin with subcuticular absorbable suture). Sterile dressing applied.
	Estimated Blood Loss (EBL)	Approximately 150 mL.
Intraoperative findings	Duration of Surgery	Approximately 100 minutes.
	Uterus & CSP	Gravid uterus consistent with 7-8 weeks size. CSP clearly identified on the anterior lower segment. Surrounding myometrium appeared thinned at the scar site. No evidence of uterine rupture or active bleeding from the CSP site prior to excision.
	Adnexa (Ovaries & Tubes)	Both ovaries and fallopian tubes (prior to fimbriectomy) appeared grossly normal.
Histopathology report	Other Pelvic Structures	Bladder, bowel, and other pelvic structures appeared grossly normal. No evidence of endometriosis or significant adhesions beyond the vesicouterine area.
	Specimen	Excised uterine scar tissue with products of conception. Bilateral fimbrial tissue.
	Microscopic Findings	Uterine tissue showing fibrous scar with embedded chorionic villi, confirming Cesarean Scar Pregnancy. Decidual reaction noted. No evidence of choriocarcinoma or invasive mole. Fimbrial tissue consistent with normal fallopian tube histology.
Post-operative management	Immediate Post-op Care (PACU)	Continuous monitoring of vital signs, oxygen saturation, pain score, and surgical site. Patient extubated successfully and transferred to ward once stable.
	Ward Management	Vital signs monitored q4h for 24h, then q8h. Intake/output charting.
	IV Fluids	Ringer Lactate 500 mL IV at 28 drops/minute continued for 12-24 hours, then switched to maintenance fluids as per hydration status.
	Analgesia	Morphine 20mg in 20mL NaCl 0.9% IV infusion at 0.8 mL/hour for the first 12-24 hours. Paracetamol 500mg PO q6h. Ibuprofen 400mg PO q8h. Pain scores maintained <3/10.
	Antihypertensive	Amlodipine discontinued. Ramipril 5mg PO once daily commenced on post-operative day 1. Blood pressure monitored closely.
	Antibiotics	Intravenous Cefazolin continued for 24 hours post-operatively (2 doses).
	Diet	Fasting maintained for 6 hours post-operatively. Sips of water allowed, then progressed to clear liquids, then soft diet, then regular diet as tolerated over 24-48 hours.
	Urinary Catheter	Indwelling urinary catheter removed 12 hours post-operatively after ensuring adequate urine output.
	Mobilization	Gradual mobilization encouraged, starting with sitting out of bed on post-operative day 1, then ambulating with assistance.
	Wound Care	Surgical wound inspected daily; dressing changed as needed. Kept clean and dry.
	DVT Prophylaxis	Early mobilization. Sequential compression devices (SCDs) applied intra-operatively and continued until fully mobile.
Discharge plan	Length of Hospital Stay	Discharged on post-operative day 3 after uneventful recovery.
	Condition at Discharge	Afebrile, hemodynamically stable, pain well-controlled with oral analgesics, ambulating independently, tolerating regular diet, bowel and bladder function normal, wound clean and dry.
	Discharge Medications	Ramipril 5mg PO daily. Ibuprofen 400mg PO PRN for pain. Paracetamol 500mg PO PRN for pain. Stool softener PRN.
	Activity Instructions	Advised to avoid strenuous activity and heavy lifting (>5kg) for 4-6 weeks. Gradual return to normal activities.
	Wound Care Instructions	Keep wound clean and dry. Monitor for signs of infection (redness, swelling, discharge, fever). Sutures subcuticular and absorbable.
	Warning Signs	Instructed to seek immediate medical attention for fever >38°C, uncontrolled pain, excessive vaginal bleeding or foul-smelling discharge, signs of wound infection, shortness of breath, or chest pain.
	Follow-up Appointment	Scheduled for review at the outpatient clinic in 1 week for wound check and symptom review, and at 6 weeks for final post-operative assessment.
	1-Week Post-operative Visit	Patient reported feeling well. Minimal incisional discomfort. Wound healing satisfactorily with no signs of infection. Vital signs stable. Blood pressure well-controlled on Ramipril.
Follow-up	6-Weeks Post-operative Visit	Complete resolution of surgical discomfort. Incision well-healed. No vaginal complaints. Speculum and bimanual examination unremarkable. Discussed histopathology report. Overall favorable outcome reported.
		Weekly serum $\beta$ -hCG levels monitored post-operatively until non-detectable (<5 mIU/mL). Levels showed consistent decline: 1 week post-op: ~1500 mIU/mL; 2 weeks: ~200 mIU/mL; 4 weeks: <5 mIU/mL.
		Advised for annual gynecological check-ups. As bilateral fimbriectomy was performed, no further obstetric follow-up specifically for pregnancy needed. Continued monitoring for hypertension with primary care physician

### 3. Discussion

This case report details the successful management of a Type I (Endogenic, COS-1), Grade II Cesarean Scar Pregnancy (CSP) in a 36-year-old, gravida 7, para 3 patient with a history of two prior cesarean sections. The presentation, diagnostic nuances, and surgical approach align with, yet offer specific insights into, this rare and potentially life-threatening form of ectopic pregnancy. The increasing incidence of CSP, paralleling rising global cesarean delivery rates, necessitates a thorough understanding of its pathophysiology, diagnosis, and diverse management strategies. CSP arises from the implantation of the blastocyst into a myometrial defect or the fibrous scar tissue of a previous uterine incision, most commonly a cesarean section. The patient in this report possessed several well-recognized risk factors: two previous cesarean sections, a history of uterine instrumentation (two D&C procedures), and an increased BMI (29.7 kg/m<sup>2</sup>). Study suggests that the number of prior cesarean sections is a significant risk factor, likely due to progressive myometrial thinning and potential for incomplete scar healing or niche formation. The original document highlights studies showing myometrial thinning and scar deficiencies increasing with the number of cesarean sections. While the exact mechanism involves trophoblastic invasion into a compromised scar, factors like poor vascularization within the scar tissue or local inflammatory responses might also play a role. This patient's history aligns with these established predisposing conditions.<sup>11,13</sup>

The clinical presentation of CSP is notoriously variable, ranging from asymptomatic incidental findings to catastrophic hemorrhage. Our patient presented with minimal vaginal discharge, a subtle symptom that underscores the need for a high index of suspicion in at-risk individuals. While vaginal bleeding and abdominal pain are common, approximately 37-40% of patients may be asymptomatic in the first trimester. Early and accurate diagnosis is paramount. Transvaginal ultrasonography (TVS), often complemented by

transabdominal views and color Doppler, remains the cornerstone of diagnosis. The diagnostic criteria applied in this case—an empty uterine cavity and endocervical canal, gestational sac implantation within the anterior lower uterine segment scar, a markedly thinned myometrium (<2-3 mm) between the sac and the bladder, and peritrophoblastic vascularity—are well-established. The use of the Cross-Over Sign (COS-1 in this case) further aided in classifying it as a Type I (endogenic) CSP, suggesting growth primarily towards the uterine cavity, which typically has a slightly better prognosis than Type II (exogenic) CSPs that invade deeply into the myometrium. The Grade II classification indicated significant scar involvement but without serosal breach. The utilization of 3D ultrasound, as in this case, can offer enhanced spatial resolution and better delineation of the sac's relationship with surrounding structures, aiding in precise classification and surgical planning.<sup>14-16</sup>

The management of CSP is complex and must be individualized based on clinical stability, gestational age, CSP type and size,  $\beta$ -hCG levels, desire for future fertility, and available expertise. Options range from expectant management (rarely chosen due to high risks of rupture and hemorrhage, especially with cardiac activity present), medical treatment (systemic or local methotrexate), to various surgical interventions. Medical management with methotrexate, particularly local injection, can be effective for early, small, non-viable CSPs or those with low  $\beta$ -hCG levels. However, its success diminishes with advancing gestation or fetal viability, and it requires prolonged follow-up. Given the live 7-8 week gestation in our patient and her desire for definitive treatment and sterilization, primary medical management was less appropriate. Surgical approaches offer higher success rates for definitive treatment. Dilation and curettage (D&C) is generally discouraged due to high risks of hemorrhage and uterine perforation. Hysteroscopic resection is a minimally invasive option suitable for Type I CSPs protruding into the cavity with adequate overlying

myometrium. Laparoscopic resection also offers minimally invasive benefits with good visualization and repair capabilities. In this case, laparotomy with wedge resection of the CSP, meticulous uterine scar repair, and concurrent bilateral fimbriectomy was chosen. This approach, while more invasive, provided excellent exposure for complete excision of the compromised scar tissue and the implanted gestation, ensured robust uterine repair, and facilitated the requested sterilization. For Type I CSPs with significant scar involvement (Grade II) or when future fertility is not desired, or if minimally invasive expertise for complex repair is limited, laparotomy remains a valid and effective option. The described technique aligns with principles of removing the pathologic tissue and restoring uterine integrity as much as possible. The successful outcome, with minimal blood loss and uneventful recovery, supports this decision.<sup>17,18</sup>

The patient had a favorable postoperative course, with resolution of the CSP confirmed by declining  $\beta$ -hCG levels and subsequent follow-up. While future fertility was not a concern due to sterilization, successful uterine repair following CSP excision can preserve fertility in many cases, though subsequent pregnancies carry increased risks of recurrence, placenta accreta spectrum, and uterine rupture, necessitating careful counseling and monitoring. This case highlights that even with a complex obstetric history and a potentially life-threatening condition like CSP, a well-executed surgical plan can lead to excellent maternal outcomes. The concurrent management of her Stage II hypertension was also an integral part of her successful perioperative care. This report adds to the body of evidence on the surgical management of Type I CSP, particularly emphasizing the utility of laparotomy for complete excision and repair in selected cases. The rising trend of cesarean deliveries globally suggests that clinicians will encounter CSP with increasing frequency, making awareness of its varied presentations, diagnostic subtleties, and comprehensive management options essential for timely intervention and the prevention of

severe maternal morbidity.<sup>19,20</sup>

#### 4. Conclusion

This case report underscores the critical importance of maintaining a high index of suspicion for cesarean scar pregnancy (CSP) in women with prior cesarean deliveries, particularly those with multiple risk factors such as high gravidity and repeated uterine surgeries. Early and precise diagnosis, heavily reliant on meticulous ultrasonography utilizing specific criteria like the Cross-Over Sign and grading of myometrial invasion, is paramount for appropriate management. The successful outcome in this complex case of a Type I, Grade II CSP, managed via laparotomy with wedge resection, uterine scar repair, and concurrent bilateral fimbriectomy, highlights the efficacy of a well-planned surgical approach tailored to the patient's specific clinical scenario and desires. This intervention not only definitively treated the life-threatening ectopic pregnancy and reinforced uterine integrity but also effectively addressed the patient's concomitant Stage II hypertension and request for permanent sterilization. Ultimately, timely diagnosis coupled with individualized, expert surgical management is crucial for optimizing maternal outcomes and preventing severe morbidity associated with this increasingly prevalent obstetric challenge.

#### 5. References

1. Thoolkar Sushil Chawla P. Case series: Management modalities of caesarean scar ectopic pregnancy. *Int J Sci Res (Raipur)*. 2024; 13(3): 617–8.
2. Savukyne E, Kliucinskas M, Malakauskiene L, Berskiene K. Cesarean section scar and placental location at the first trimester of pregnancy-A prospective longitudinal study. *Medicina (Kaunas)*. 2024; 60(5).
3. Natrella M, Department of Radiology, Hopital Parini, AUSL Valleè d'Aoste, Aosta, Italy. Bilateral uterine arteries methotrexate infusion and embolization: a new approach in patient with caesarean scar pregnancy: Case

- report and literature review. *Open J Clin Med Case Rep.* 2024; 10(11).
4. Devarajan A, Tiwari M, Gangoo C. Life threatening acute abdomen with ruptured caesarean scar pregnancy: Surgical management with preservation of uterus. *Int J Clin Obstet Gynaecol.* 2024; 8(3): 115–6.
  5. Hamed I, Abdelrazik M, El-Zayadi A. Manual vacuum aspiration alone versus manual vacuum aspiration preceded by methotrexate in management of caesarean scar pregnancy. *Evid Based Women S Health J.* 2024; 14(2): 215–9.
  6. Lei Y, Du X, Liu Y, Le F, Zhou J. Surgical treatment and reproductive outcomes in caesarean scar pregnancy at a single center. *Reprod Biol Endocrinol.* 2024; 22(1): 54.
  7. Machairiotis N, Stavros S, Antonakopoulos N, Vrachnis D, Potiris A, Fotiou A, et al. Ectopic pregnancy with full implantation of the gestational sac in the caesarean section scar managed successfully with laparotomy. *Clin Case Rep.* 2024; 12(6): e9087.
  8. Walker S, Grant S, O'Brien S, Weale N, Crofts J, Vieten-Kay D, et al. Caesarean scar pregnancy presenting at 17 weeks with a journey involving an exploratory laparotomy, continuing pregnancy and delivery at 34 weeks: a case report. *Case Rep Womens Health.* 2024; 42(e00626): e00626.
  9. Simon A, Hanocq F, Delbecque K, Kridelka F, Nervo P. TruClear™ treatment of caesarean scar pregnancy interrupted after methotrexate injection. *Rev Med Liege.* 2024; 79(7–8): 527–31.
  10. Marwah S, Agarwal A, Saini R, Balayan A. Pregnancy over caesarean scar site-account of four unusual cases in the form of a case series. *Int J Reprod Contracept Obstet Gynecol.* 2024; 13(8): 2119–24.
  11. Samir Mehta A, A Yadava P. Caesarean scar ectopic pregnancy: a case report. *Int J Sci Res (Raipur).* 2024; 13(8): 764–5.
  12. Nwankwo ME, Egeonu RO, Ikeotuonye AC, Eleje GU, Okafor CO, Ikpeze GC, et al. Diagnostic and management challenges of a rare case of caesarean scar pregnancy in a low-resource setting: a case report. *SAGE Open Med Case Rep.* 2024; 12: 2050313X241286670.
  13. Akanda M, Karim MR, Busreea RA, Begum F, Mukstadira, Sen S, et al. Failed medical management of a caesarean scar pregnancy leading to manual vacuum aspiration and hysterotomy: a case report. *Comm Based Med J.* 2025; 14(1): 163–7.
  14. Lim LS, Melville L. Caesarean scar ectopic pregnancy. *Pathology.* 2025; 57: S60.
  15. Toutain T, Capmas P, Fernandez H, Couet D, Pourcelot A-G, Debras E. Local and systemic methotrexate in management of caesarean scar pregnancy. *Eur J Obstet Gynecol Reprod Biol.* 2025; 305: 37–41.
  16. Toutain T, Capmas P, Fernandez H, Couet D, Pourcelot A-G, Debras E. Local and systemic methotrexate in management of caesarean scar pregnancy. *Eur J Obstet Gynecol Reprod Biol.* 2025; 305: 37–41.
  17. Rodrigo SNK, Gunasekera ED, Dhanaratna D. Caesarean section scar pregnancy: expectant management with favourable outcome of an acute presentation. *BMJ Case Rep.* 2025; 18(3).
  18. Bonetti E, La Fera E, Alesi MV, D'Ippolito S, Lanzzone A, Scambia G, et al. Conservative management of caesarean scar pregnancy: tissue removal device hysteroscopic treatment after uterine artery embolisation. *Facts Views Vis ObGyn.* 2025; 17(1): 90–3.
  19. Fu L, Yuan H, Cao H, Zhou Q, Tan X, Guo J. Clinical value of ultrasonic indicators in predicting the outcome of caesarean scar pregnancy after pregnancy termination. *BMC Pregnancy Childbirth.* 2023; 23(1): 863.

20. Du Z, Xu W, Lu J, Li C. Comparison of clinical safety and efficacy of ultrasound-guided local lauromacrogol injection versus uterine artery embolization in the treatment of caesarean scar pregnancy: a systematic review and meta-analysis. *BMC Pregnancy Childbirth*. 2023; 23(1): 149.