



Bioscientia Medicina: Journal of Biomedicine & Translational Research

Journal Homepage: www.bioscmed.com

The Importance of Dermoscopy for Early Recognition of Superficial Spreading Melanoma in Adolescents: A Case Report

Cherry Chalik^{1*}, Ennesta Asri¹, Indah Indria Sari¹

¹Department of Dermatology, Venereology and Esthetics, Faculty of Medicine, Universitas Andalas/Dr. M. Djamil General Hospital, Padang, Indonesia

ARTICLE INFO

Keywords:

Adolescent
Case report
Dermoscopy
Early diagnosis
Melanoma

*Corresponding author:

Cherry Chalik

E-mail address:

cherrychalik@gmail.com

All authors have reviewed and approved the final version of the manuscript.

<https://doi.org/10.37275/bsm.v9i3.1216>

ABSTRACT

Background: Malignant melanoma, a highly aggressive form of skin cancer, is rare in adolescents. Early diagnosis is crucial for the best possible treatment and prognosis. Dermoscopy, a non-invasive technique, has been shown to increase the sensitivity of melanoma diagnosis, leading to early identification and better treatment outcomes. **Case presentation:** A 14-year-old female presented with a painful, bleeding black nevus on her right upper arm, increasing in size over four months. Dermoscopic examination, using a two-step algorithm and the ABCD rule, categorized the lesion as malignant melanoma. Histopathological examination confirmed the diagnosis of superficial spreading melanoma (Breslow 2, AJCC stage IIB). The patient underwent Mohs surgery for treatment. **Conclusion:** This case highlights the importance of dermoscopy in the early recognition of melanoma in adolescents. Dermoscopy aids in differentiating between benign and malignant melanocytic lesions, enabling prompt diagnosis and treatment. Increased awareness and utilization of dermoscopy can significantly improve outcomes in this patient population.

1. Introduction

Melanoma, a malignancy originating from melanocytes, stands as a formidable challenge in dermatological practice. Its propensity for aggressive behavior and metastatic spread underscores the critical importance of early detection and prompt intervention. While melanoma incidence has been steadily rising across all age groups, it remains relatively rare in the adolescent population. However, this rarity should not engender complacency, as delayed diagnosis in young individuals can have profound consequences, potentially impacting their long-term health and well-being. Melanoma's global impact is undeniable. In the United States alone, an

estimated 91,270 new cases were diagnosed in 2018, highlighting the pervasive nature of this disease. The principal risk factor for melanoma development is exposure to ultraviolet (UV) radiation, primarily from sunlight. While genetic predisposition and immune system dysfunction also play contributing roles, UV radiation remains the most significant modifiable risk factor.¹⁻³

Melanoma in adolescents presents a unique diagnostic challenge. The relative rarity of this condition in young people can lead to delayed diagnosis, as clinicians may not initially consider melanoma in their differential diagnosis. Moreover, the clinical presentation of melanoma in adolescents

can be atypical, mimicking benign lesions such as nevi or dermatofibromas. This further complicates the diagnostic process, potentially hindering early recognition and timely intervention. Dermoscopy, also known as epiluminescence microscopy, has emerged as a revolutionary tool in the evaluation of pigmented skin lesions. This non-invasive technique involves the use of a handheld device, a dermatoscope, which illuminates and magnifies the skin, allowing for detailed visualization of subsurface structures not visible to the naked eye. By enhancing the visualization of these subtle features, dermoscopy empowers clinicians to differentiate between benign and malignant lesions with greater accuracy. The integration of dermoscopy into clinical practice has led to a paradigm shift in melanoma diagnosis. Studies have consistently demonstrated that dermoscopy significantly improves the sensitivity and specificity of melanoma detection, particularly when used in conjunction with clinical examination. This translates to earlier diagnosis, more effective treatment strategies, and ultimately, improved patient outcomes.⁴⁻⁷

Dermoscopic evaluation often employs a two-step algorithm in conjunction with the ABCD rule to guide the diagnostic process. The two-step algorithm categorizes lesions based on their global and local patterns, while the ABCD rule assesses Asymmetry, Border irregularity, Color variegation, and Diameter. This structured approach enhances the accuracy and reproducibility of dermoscopic interpretations. Mohs micrographic surgery has emerged as the gold standard for the surgical management of melanoma. This meticulous technique involves the removal of the tumor layer by layer, with immediate microscopic examination of each layer to ensure complete tumor eradication. Mohs surgery offers the highest cure rates while minimizing the removal of healthy tissue, making it a preferred option for many melanoma patients.⁸⁻¹⁰ The case report presented herein underscores the critical importance of dermoscopy in the early recognition of melanoma in adolescents.

2. Case Presentation

This report details the case of a 14-year-old female who presented to our dermatology clinic with a concerning pigmented lesion on her right upper arm. The lesion had been present for an extended period, initially appearing as an innocuous black nevus. However, over the preceding four months, the patient and her parents observed several worrisome changes that prompted them to seek medical evaluation. These changes included a noticeable increase in the lesion's size, the onset of pain, and occasional bleeding episodes. A comprehensive medical history was obtained from the patient and her parents. The patient reported no significant past medical history, allergies, or family history of skin cancer. She denied excessive sun exposure or use of tanning beds. However, she did report spending a considerable amount of time outdoors for recreational activities. The patient's primary complaint centered on the evolving nature of the pigmented lesion. She described a gradual increase in size, accompanied by intermittent pain and bleeding, particularly upon accidental contact or friction with clothing. These symptoms caused significant anxiety and concern for both the patient and her family. A thorough physical examination was performed, with particular attention to the affected area on the right upper arm. Upon visual inspection, the lesion presented as a hyperpigmented plaque with an erythematous base, measuring approximately 1 cm x 0.5 cm. The lesion's borders appeared irregular, and there was noticeable variation in color, ranging from dark brown to black. Palpation revealed a slightly raised and firm consistency. No regional lymphadenopathy was detected. Given the lesion's suspicious clinical features, dermoscopy was performed to further evaluate its morphology and aid in the diagnostic process. Dermoscopy, also known as epiluminescence microscopy, is a non-invasive technique that allows for detailed visualization of subsurface skin structures not visible to the naked eye. Using a handheld dermatoscope, the lesion was examined under polarized light. The dermoscopic findings were analyzed using a two-step algorithm and

the ABCD rule, both widely recognized methods for evaluating pigmented skin lesions. The two-step algorithm, which categorizes lesions based on their global and local patterns, identified the lesion as melanocytic in nature. Further assessment using the ABCD rule, which assesses Asymmetry, Border irregularity, Color variegation, and Diameter, revealed features suggestive of malignancy. Specifically, the lesion exhibited marked asymmetry, irregular borders, multiple colors (including black, brown, and blue), and a diameter greater than 6 mm. To assess the extent of the disease and rule out any regional or distant metastasis, imaging studies were ordered. Ultrasound examination of the axillary lymph nodes bilaterally revealed no evidence of lymphadenopathy. A chest X-ray was also performed and showed no abnormalities. Following the clinical and dermoscopic evaluation, an excisional biopsy of the lesion was performed. The tissue specimen was submitted for histopathological examination, which confirmed the diagnosis of superficial spreading melanoma. The Breslow thickness, a measure of the tumor's vertical depth, was determined to be 2 mm. Based on the American Joint Committee on Cancer (AJCC) staging system, the patient's melanoma was classified as stage IIB. Integrating the clinical, dermoscopic, and histopathological findings, a definitive diagnosis of superficial spreading melanoma was established. The patient's young age and the lesion's location on the upper arm, an area not typically associated with high sun exposure, highlight the importance of maintaining a high index of suspicion for melanoma in all age groups and body sites (Table 1).

Following the definitive diagnosis of superficial spreading melanoma, a multidisciplinary team, including dermatologists, surgeons, and oncologists, convened to formulate a comprehensive treatment plan tailored to the patient's specific needs. The primary goal of treatment was to achieve complete tumor eradication while minimizing morbidity and preserving the patient's quality of life. The mainstay of treatment for melanoma is surgical excision. In this case, Mohs micrographic surgery was deemed the

most appropriate surgical approach. Mohs surgery is a highly specialized technique that involves the removal of the tumor layer by layer, with immediate microscopic examination of each layer to ensure complete removal of all cancerous cells. This meticulous approach offers the highest cure rates while minimizing the removal of healthy tissue, making it a preferred option for many melanoma patients, particularly those with lesions in cosmetically sensitive areas. The patient underwent Mohs micrographic surgery under general and tumescent anesthesia. Tumescent anesthesia involves the injection of a large volume of local anesthetic solution into the surgical area, which helps to minimize bleeding and improve visualization of the tumor margins. Flap reconstruction was performed to close the surgical defect and optimize cosmetic outcomes. In addition to surgical excision, systemic treatment was considered to address the potential for microscopic residual disease and reduce the risk of recurrence. The patient received intravenous ceftriaxone, a broad-spectrum antibiotic, to prevent postoperative infection. Tranexamic acid, an antifibrinolytic agent, was administered orally for three days to minimize bleeding. Supportive care measures were also implemented to manage postoperative pain and promote wound healing. Paracetamol, a non-opioid analgesic, was prescribed for pain relief. Vitamin K, a fat-soluble vitamin essential for blood clotting, was given to reduce the risk of bleeding complications. Vitamin C, an antioxidant with wound-healing properties, was also included in the systemic treatment regimen. Topical treatment played a crucial role in postoperative wound management. Fusidic acid ointment, a topical antibiotic, was applied to the surgical site to prevent infection and promote healing. The ointment was applied twice daily, initially after surgery and subsequently during wound dressing changes. Close follow-up was essential to monitor the patient's recovery and detect any signs of recurrence. The patient was scheduled for regular follow-up appointments at the dermatology clinic for dressing

changes and wound assessment. On day 7 postoperatively, the patient reported mild pain in the surgical area, but there was no evidence of swelling, bleeding, infection, hematoma, or necrosis. The wound was healing well, with minimal erythema and no signs of complications. By day 14, the pain had subsided significantly, and the wound edges were dry and well-approximated. There was no evidence of infection, necrosis, fever, or discharge. The stitches were removed, and the wound continued to heal favorably, with minimal erythema, no edema or pus, and an intact flap. The scar appeared eutrophic, indicating healthy tissue regeneration. In addition to routine dermatological follow-up, the patient was also referred for consultation with a pediatric hemato-oncologist to assess the need for further systemic therapy or adjuvant treatment. Magnetic resonance imaging (MRI) was also recommended to evaluate for any evidence of regional or distant metastasis. The patient's case highlights the importance of a multidisciplinary approach in the management of melanoma. By integrating surgical expertise, systemic therapy, and meticulous wound care, optimal outcomes can be achieved, even in young patients with challenging presentations. Continued vigilance and close follow-up are crucial to ensure long-term disease-free survival and maintain the patient's overall well-being (Table 2).

Dermoscopy played a crucial role in the evaluation of the pigmented lesion in this case. This non-invasive technique, also known as epiluminescence microscopy, involves the use of a handheld device called a dermatoscope, which illuminates and magnifies the skin, allowing for detailed visualization of subsurface structures not visible to the naked eye. In this case, dermoscopy was performed using polarized light, which enhances the visualization of pigment patterns and other subtle features. The examination revealed a complex interplay of dermoscopic structures, each contributing to the overall assessment of the lesion. A prominent pigment network was observed, characterized by a reticular pattern of interconnected brown lines. This finding is

often associated with benign melanocytic lesions, such as nevi. However, the presence of a pigment network does not definitively rule out malignancy, as some melanomas can also exhibit this feature. In addition to the pigment network, areas of negative pigment network were also identified. These areas, devoid of pigment, appeared as whitish or pinkish patches within the lesion. The presence of both pigment network and negative pigment network within the same lesion can be a concerning finding, raising the suspicion for melanoma. Angulated lines, another important dermoscopic feature, were not observed in this case. Angulated lines are sharp, geometric lines that often appear in melanoma, particularly in the radial growth phase. The absence of angulated lines does not exclude the possibility of melanoma, but it can be a helpful clue in differentiating between benign and malignant lesions. Streak or starburst patterns were identified within the lesion. These patterns, characterized by linear streaks or radiating lines of pigment, are often associated with melanoma. They represent areas of pigment regression, a phenomenon commonly seen in melanoma as the tumor cells destroy the surrounding melanocytes. Globular patterns were also observed, appearing as round or oval areas of homogenous pigmentation. Globular patterns can be seen in both benign and malignant melanocytic lesions, but their presence in conjunction with other suspicious features, such as streak or starburst patterns, increases the likelihood of melanoma. Peripheral rim or globules, pseudonetwork, and homogenous blue pigmentation were not observed in this case. These features, while sometimes seen in melanoma, are not essential for the diagnosis. Based on the overall dermoscopic findings, particularly the presence of negative pigment network, streak or starburst patterns, and globular patterns, the lesion was categorized as a melanocytic lesion with a high suspicion for malignancy. This assessment prompted further investigation, including histopathological examination, to confirm the diagnosis (Table 3).

The ABCD rule of dermoscopy is a widely used mnemonic to assess pigmented skin lesions for suspicious features suggestive of melanoma. It stands for Asymmetry, Border irregularity, Color variegation, and Diameter. Each criterion is evaluated and scored based on its degree of abnormality, with higher scores indicating a greater likelihood of malignancy. The lesion in this case exhibited marked asymmetry, scoring 2 points according to the ABCD rule. Two axes, one longitudinal and one perpendicular, were drawn through the center of the lesion. The two halves of the lesion, when compared along each axis, showed significant differences in shape and structure. This asymmetry is a hallmark of melanoma, as benign lesions tend to be more symmetrical. The border of the lesion was markedly irregular, also scoring 2 points. The border exhibited notching, scalloping, and blurring in several areas. These irregularities are often seen in melanoma as the tumor grows and invades the surrounding skin. In contrast, benign lesions typically have smooth, well-defined borders. The lesion displayed a striking variegation of colors, earning it 2 points on the color criterion. Multiple colors were observed, including black, brown, blue-gray, and red. This diversity of colors is another characteristic

feature of melanoma, reflecting the presence of different types of melanin and blood vessels within the tumor. Benign lesions, on the other hand, tend to have a more uniform color. The lesion measured greater than 6 mm in diameter, scoring 2 points for this criterion. While the exact diameter was not specified in the table, it clearly exceeded the 6 mm threshold, which is often used as a cutoff for suspicious pigmented lesions. Melanomas can vary in size, but lesions larger than 6 mm warrant closer scrutiny. The total dermoscopy score, obtained by summing the individual scores for each ABCD criterion, was 8. This high score strongly suggests a malignant melanoma. While the ABCD rule is not a definitive diagnostic tool, it serves as a valuable aid in identifying suspicious lesions that require further investigation, such as a biopsy and histopathological examination. In this case, the high ABCD score, coupled with the concerning clinical presentation and the findings from the first step of the dermoscopic examination, prompted a biopsy and subsequent histopathological confirmation of the diagnosis of superficial spreading melanoma. This case underscores the importance of the ABCD rule as a practical and effective tool in the evaluation of pigmented skin lesions (Table 4).

Table 1. Anamnesis, physical examination, imaging, histopathology, and diagnosis.

Category	Findings
Anamnesis	14-year-old female with a black nevus on her right upper arm, increasing in size, painful, and occasionally bleeding over the past four months.
Physical examination	Hyperpigmented plaque with an erythematous base, measuring 1 cm x 0.5 cm (Figure 1).
Dermoscopy	Two-step algorithm: Melanocytic lesion (Table 3). ABCD rule: Malignant melanoma (Table 4).
Imaging	Ultrasound of lymph nodes: No bilateral axillary lymphadenopathy. Chest X-ray: Within normal limits.
Histopathology	Superficial spreading melanoma, Breslow thickness 2 mm (AJCC stage IIB) (Figure 2).
Diagnosis	Superficial spreading melanoma.

Table 2. Treatment and follow-up.

Category	Details
Surgical treatment	Mohs micrographic surgery under general and tumescent anesthesia with flap reconstruction.
Systemic treatment	Ceftriaxone 2 x 1 gr (IV) Tranexamic acid 3 x 500 mg PO (per oral) for 3 days Paracetamol 3 x 500 mg PO for 3 days Vitamin K 1 x 10 mg PO for 3 days Vitamin C 1 x 50 mg PO for 3 days
Topical treatment	Fusidic acid ointment 2% applied postoperatively and during wound dressing.
Follow up	Day 7: Pain in the surgical area was mild, no swelling, bleeding, infection, hematoma, or necrosis. Day 14: Pain in the surgical area was mild, wound edge dry, no infection, necrosis, fever, or discharge. Stitches removed, wound edge erythema minimal, no edema or pus, flap intact, eutrophic scar. Follow-up appointments at the dermatology clinic for dressing changes. Consultation with Pediatric Hemato-Oncology. MRI.

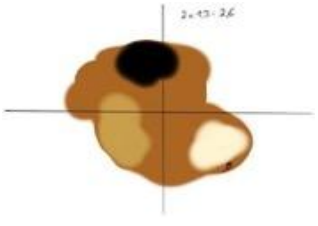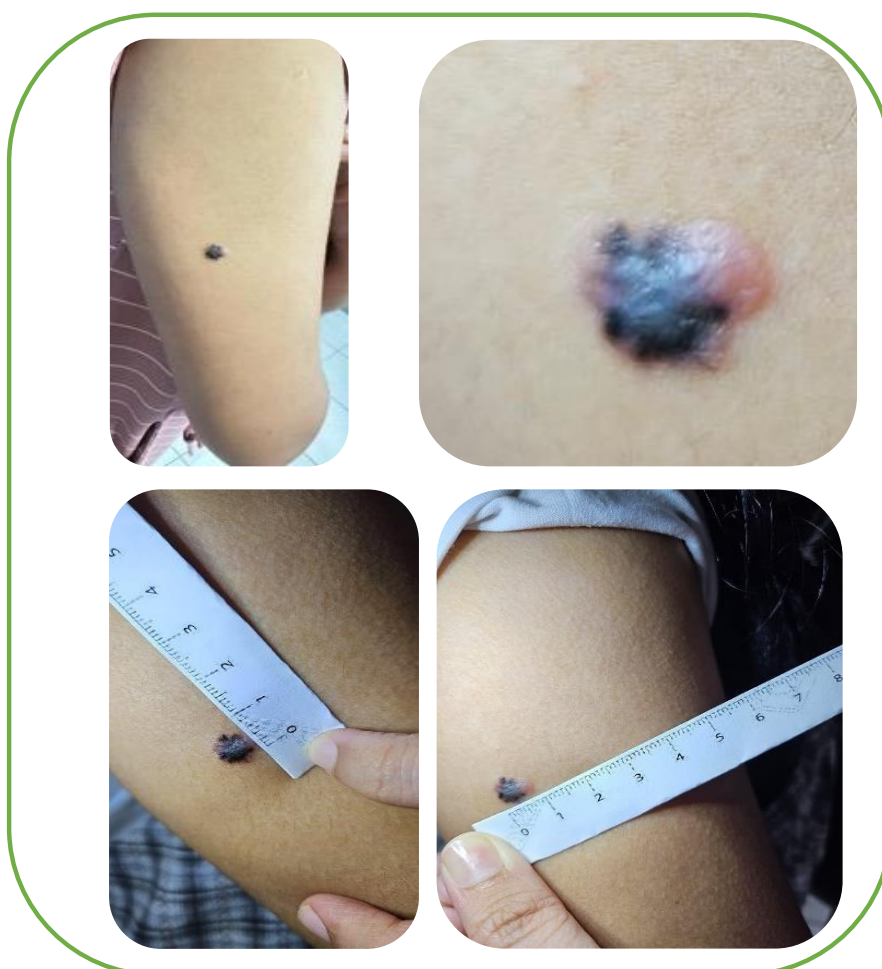
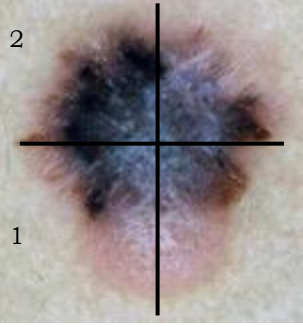
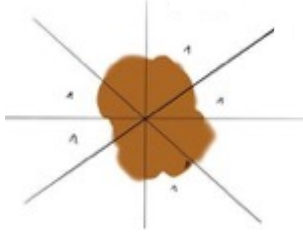




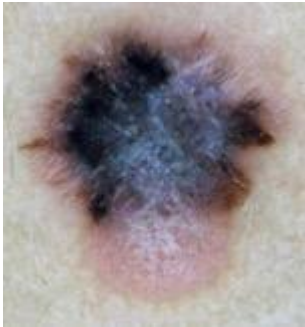
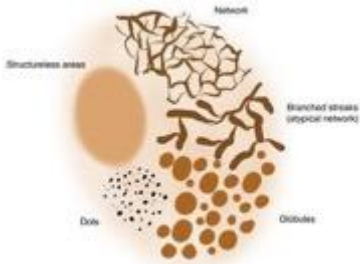
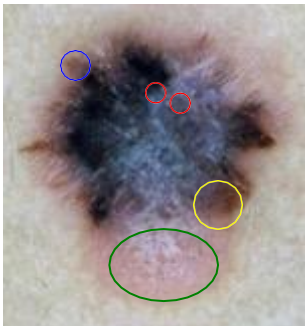
Figure 1. Hyperpigmented plaque with erythema base in the periphery, multicoloured, and irregularly sized upper arm 1x 0,5 cm.

Table 3. Dermoscopy examination findings (First Step).

Feature	Presence
Pigment network	✓
Negative pigment network	✓
Angulated line	-
Streak or starburst pattern	✓
Globular pattern	✓
Peripheral rim or globules	-
Pseudonetwork	-
Homogenous blue	-
Result	Melanocytic lesion

Table 4. ABCD scoring (Second Step).

Criteria	Score	Coefficient	Sub-score
A = Asymmetry The lesion is divided by two mutually perpendicular lines. The first line divides the lesion into 2 “most symmetrical” halves and the other line is then placed at 90° to the first line. Symmetry or asymmetry by analyzing the color and structure within the lesion. 	2 Asymmetric axis  Asymmetry in axis 1 and 2	1,3	2,6
B = Border irregularity First, the lesion was divided into eight equal parts. Then count the sections that have irregular boundaries (firm boundaries immediately followed by unclear boundaries in 1 section). 	 Score 7 Irregular boundaries in almost all segments, except segment 4	0,1	0,7

<p>C = Color The colors assessed are: white, red, light brown, bluish gray and black. Each color has a value of 1</p> 	 <p>Appears black, white, red, bluish gray, light brown, dark brown. Score = 6</p>	0,5	3
<p>D = Differentiated structures The structures assessed are pigment network, structureless area, dot, globule, and branched streak. Each structure has a value of 1.</p> 	 <p>Dots (red circle), branched streaks (blue circle), structureless areas (green cycle), and globules (yellow cycle) are visible. Score = 4</p>	0,5	2
<p>Dermoscopy Total Score</p>		8,3 Melanoma	

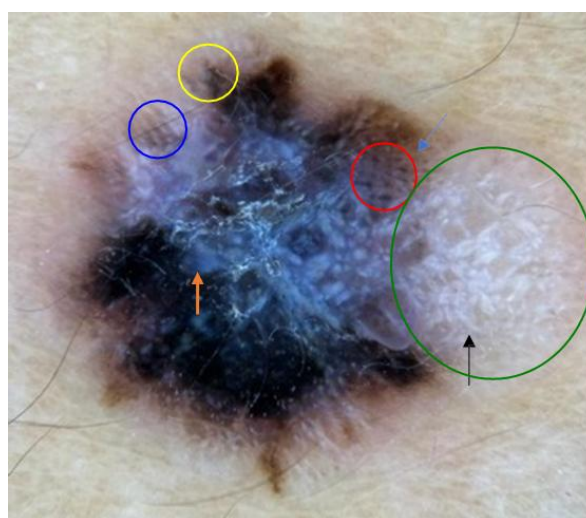


Figure 2. Dermatoscopic aspect: atypical dot and globules (red circle), negative pigment network (blue circle), regression structure (green circle), blue white veil (orange arrow), atypical pigment network (blue arrow), shiny white line (black arrow), irregular streak (yellow circle).

3. Discussion

Melanoma, while less prevalent in adolescents than in adults, presents a unique challenge due to its potential for rapid progression and metastasis. The aggressive nature of melanoma underscores the critical importance of early diagnosis and prompt intervention in this age group. Delayed diagnosis can have profound consequences, impacting not only the patient's physical health but also their emotional and psychological well-being. Adolescents diagnosed with melanoma often face a complex interplay of physical, social, and psychological challenges that can significantly affect their quality of life. Early detection allows for timely intervention, significantly increasing the chances of successful treatment and long-term survival. When melanoma is identified and treated in its early stages, before it has spread to regional lymph nodes or distant organs, the prognosis is generally favorable. The earlier the melanoma is detected, the less invasive the treatment options are likely to be, and the higher the chances of avoiding more aggressive treatments like chemotherapy or radiation therapy. Moreover, early diagnosis can help preserve the patient's quality of life by minimizing disruptions to their daily activities and social interactions. To elaborate further, the stage of melanoma at diagnosis is a crucial determinant of prognosis. The stage refers to the extent of the cancer's spread within the body. Early-stage melanomas (Stages 0, I, and II) are confined to the skin or have minimal spread to nearby lymph nodes. These stages have high 5-year survival rates, often exceeding 90%. However, as melanoma progresses to later stages (Stages III and IV), involving more extensive lymph node involvement or distant metastases, the survival rates decline significantly. Early diagnosis allows for prompt surgical intervention, which is the primary treatment for early-stage melanoma. Surgical excision with adequate margins effectively removes the tumor and minimizes the risk of recurrence. In some cases, sentinel lymph node biopsy may be performed to assess for regional lymph node involvement. If the sentinel lymph node is negative, further surgery is usually not required.

However, if the sentinel lymph node is positive, a complete lymph node dissection may be necessary. For advanced-stage melanomas, treatment options may include surgery, radiation therapy, chemotherapy, targeted therapy, immunotherapy, or a combination of these modalities. These treatments can have significant side effects and may not be as effective as surgery in early-stage melanoma. Therefore, early diagnosis is crucial to maximize the chances of successful treatment and long-term survival. Early-stage melanoma can often be treated with less invasive surgical procedures, preserving healthy tissue and minimizing scarring. This is particularly important for adolescents who may be more self-conscious about their physical appearance and body image. Less invasive procedures also typically result in faster recovery times, fewer complications, and reduced pain, allowing adolescents to return to their normal activities sooner. Additionally, minimizing scarring can help alleviate potential psychological distress associated with visible reminders of the disease. Surgical techniques for melanoma removal have evolved significantly in recent years, with a focus on minimizing invasiveness and preserving healthy tissue. For thin melanomas (less than 1 mm thick), a simple excision with a small margin of healthy skin may be sufficient. For thicker melanomas, wider excision margins may be necessary, and techniques such as Mohs micrographic surgery can be used to ensure complete tumor removal while minimizing tissue loss. Mohs surgery is a specialized technique in which the surgeon removes the tumor layer by layer, examining each layer under a microscope until all cancerous cells are removed. This technique is particularly useful for melanomas located in cosmetically sensitive areas, such as the face, where preserving healthy tissue is crucial. Less invasive surgical procedures not only minimize scarring but also reduce the risk of complications such as infection, bleeding, and nerve damage. Additionally, they allow for faster recovery times and a quicker return to normal activities, which is particularly important for adolescents who are eager to resume their social and

academic lives. Early and complete removal of the melanoma significantly reduces the risk of recurrence and the need for more aggressive treatment modalities such as chemotherapy or radiation therapy. Recurrence of melanoma can be a significant setback for adolescents, both physically and emotionally. By reducing the risk of recurrence, early diagnosis and treatment can help adolescents avoid the need for additional treatments and their associated side effects, allowing them to focus on their recovery and return to normalcy. Melanoma has a tendency to recur, either locally at the original site or distantly in other parts of the body. The risk of recurrence is influenced by several factors, including the thickness of the melanoma, the presence of ulceration, and the involvement of lymph nodes. Early diagnosis and complete surgical removal of the melanoma significantly reduce the risk of recurrence. Studies have shown that the 5-year recurrence rate for thin melanomas (less than 1 mm thick) is less than 5% after complete surgical excision. However, the recurrence rate increases with the thickness of the melanoma, reaching up to 20% for melanomas thicker than 4 mm. Recurrence of melanoma can be a devastating event for adolescents, both physically and emotionally. It can lead to anxiety, depression, and fear of the future. By reducing the risk of recurrence, early diagnosis and treatment can help adolescents avoid these psychological burdens and allow them to focus on their recovery and return to a normal life. Early diagnosis and treatment can help adolescents maintain their normal activities and social interactions, minimizing disruptions to their lives and promoting a sense of normalcy. Adolescence is a critical period of social, emotional, and physical development, and disruptions to this process can have long-lasting consequences. Early diagnosis and treatment of melanoma can help adolescents maintain their peer relationships, continue their education, and participate in extracurricular activities, all of which contribute to their overall well-being and quality of life. Adolescence is a time of significant transitions and challenges, as individuals navigate the path to

adulthood. A diagnosis of melanoma can disrupt this delicate process, leading to social isolation, academic difficulties, and emotional distress. Early diagnosis and treatment can help minimize these disruptions and allow adolescents to maintain a sense of normalcy. By returning to their normal activities and social interactions, adolescents can maintain their peer relationships, continue their education, and participate in extracurricular activities, all of which are essential for their overall well-being and development. Moreover, early diagnosis and treatment can help adolescents avoid the psychological burdens associated with a cancer diagnosis, such as anxiety, depression, and fear of the future. By addressing these psychological needs, healthcare professionals can help adolescents cope with their diagnosis and maintain a positive outlook on life. In addition to these key benefits, early diagnosis of melanoma in adolescents also has broader implications for public health. By identifying and treating melanoma early, healthcare professionals can gather valuable data on the disease's progression and treatment outcomes in this specific age group. This information can be used to refine treatment protocols, develop targeted interventions, and improve overall survival rates for adolescents with melanoma. Furthermore, early diagnosis can raise awareness of melanoma among adolescents, their families, and the broader community. This increased awareness can lead to more proactive sun-safety practices, earlier detection of suspicious skin lesions, and ultimately, a reduction in the incidence of melanoma in this age group.¹¹⁻¹⁴

Dermoscopy, a non-invasive imaging technique, has revolutionized the diagnosis of melanoma by enabling detailed visualization of subsurface skin structures not visible to the naked eye. This technology empowers clinicians to differentiate between benign and malignant lesions with greater accuracy, leading to earlier diagnosis and improved patient outcomes. The integration of dermoscopy into clinical practice has led to a paradigm shift in melanoma diagnosis. Studies have consistently demonstrated that dermoscopy significantly improves

the sensitivity and specificity of melanoma detection, particularly when used in conjunction with clinical examination. This translates to earlier diagnosis, more effective treatment strategies, and ultimately, improved patient outcomes. Dermoscopy's ability to enhance diagnostic accuracy stems from its ability to reveal subtle features that may be indicative of malignancy. These features, often imperceptible to the naked eye, provide crucial clues about the underlying structure and organization of pigmented lesions, enabling clinicians to distinguish between benign and malignant melanocytic proliferations with greater confidence. Melanomas often exhibit irregular shapes and asymmetrical patterns, unlike benign lesions, which tend to be more symmetrical. This asymmetry reflects the disordered growth pattern of melanoma cells, which proliferate in an uncontrolled manner, leading to irregular shapes and uneven distribution of pigment. The borders of melanoma lesions are often poorly defined, notched, or blurred, while benign lesions typically have smooth, well-defined borders. This irregularity reflects the invasive nature of melanoma, as the tumor cells infiltrate the surrounding skin, disrupting the normal architecture and creating irregular borders. Melanomas can display a variety of colors within the same lesion, including shades of brown, black, blue, gray, and red. Benign lesions usually have a more uniform color. This color variegation in melanoma is due to the presence of different types of melanin, as well as changes in blood flow and inflammation within the tumor. Melanomas are often larger than 6 mm in diameter, although smaller melanomas can occur. Benign lesions are typically smaller. While size alone is not a definitive diagnostic criterion, larger lesions warrant closer scrutiny, as they may harbor more aggressive melanomas. Changes in the size, shape, color, or symptoms of a pigmented lesion can be a significant indicator of melanoma. These changes reflect the dynamic nature of melanoma, as the tumor cells continue to proliferate and invade the surrounding tissues. Any new or changing lesion should be evaluated promptly by a dermatologist.

Atypical or disrupted pigment networks can be a sign of melanoma. The pigment network, a delicate meshwork of brown lines visible under dermoscopy, represents the distribution of melanin within the epidermis. In melanoma, this network is often disrupted, irregular, or absent, reflecting the disorganized growth of melanocytes. Areas devoid of pigment within a lesion can be a concerning finding. These areas, known as "regression," represent areas where the melanoma has destroyed the normal melanocytes, leaving behind a pale or white scar-like appearance. Regression is often associated with more aggressive melanomas. Sharp, geometric lines are often associated with melanoma, particularly in the radial growth phase. These lines, which may appear as sharp angles or polygons, reflect the architectural disarray within the epidermis caused by the proliferating melanoma cells. Linear streaks or radiating lines of pigment can indicate areas of regression, a phenomenon commonly seen in melanoma. These streaks represent areas where the melanoma has regressed, leaving behind linear trails of pigment. Round or oval areas of homogenous pigmentation can be seen in both benign and malignant lesions, but their presence in conjunction with other suspicious features increases the likelihood of melanoma. Globules represent clusters of melanocytes, and their presence in a disorganized or atypical pattern can raise suspicion for melanoma. A hazy blue-white coloration can be indicative of melanoma. This veil, which may be diffuse or localized, is thought to be caused by light scattering within the tumor, reflecting the presence of inflammatory cells and abnormal blood vessels. These lines, often seen within the pigment network, can be a subtle sign of melanoma. Shiny white lines are thought to represent areas of fibrosis or scarring within the tumor, reflecting the invasive nature of melanoma. Streaks of pigment that are uneven in thickness or distribution can be a suspicious finding. These streaks may represent areas of regression or irregular pigment production within the melanoma. By carefully evaluating these dermoscopic features, clinicians can

gain a more comprehensive understanding of a pigmented lesion's morphology and make a more informed diagnostic decision. Dermoscopy is particularly useful in differentiating between benign melanocytic nevi and early melanoma, which can often have similar clinical appearances. Furthermore, dermoscopy can help identify melanomas that may not be readily apparent to the naked eye, such as amelanotic melanomas, which lack pigment, and desmoplastic melanomas, which have a scar-like appearance. These melanomas can be easily overlooked during a clinical examination, but dermoscopy can reveal subtle features that raise suspicion for malignancy. Amelanotic melanomas, which lack pigment, can be particularly challenging to diagnose clinically, as they may appear as pink or red papules or nodules. Dermoscopy can help identify subtle features such as atypical vascular patterns, shiny white lines, and blue-white veil, which can raise suspicion for amelanotic melanoma. Desmoplastic melanomas, which have a scar-like appearance, can also be difficult to diagnose clinically, as they may mimic benign scars or dermatofibromas. Dermoscopy can reveal subtle features such as atypical vascular patterns, irregular streaks, and angulated lines, which can suggest desmoplastic melanoma. The use of dermoscopy has been shown to improve the accuracy of melanoma diagnosis, particularly when used by trained clinicians. Studies have demonstrated that dermoscopy can increase the sensitivity of melanoma detection by up to 20% and the specificity by up to 10% compared to clinical examination alone. This translates to earlier diagnosis, more effective treatment strategies, and ultimately, improved patient outcomes. By enabling earlier diagnosis, dermoscopy allows for prompt surgical intervention, which is the primary treatment for early-stage melanoma. Early surgical excision with adequate margins effectively removes the tumor and minimizes the risk of recurrence. This can lead to improved survival rates and a better quality of life for patients. In addition to its diagnostic value, dermoscopy can also be used to monitor pigmented lesions over time. By documenting

the dermoscopic features of a lesion at regular intervals, clinicians can detect subtle changes that may suggest malignant transformation. This can lead to earlier intervention and potentially prevent the progression of melanoma to a more advanced stage. Digital dermoscopy, which allows for the capture and storage of dermoscopic images, has further enhanced the ability to monitor lesions over time. By comparing images taken at different time points, clinicians can detect subtle changes that may not be apparent during a single examination. This can lead to earlier detection of melanoma and improved patient outcomes.¹⁵⁻¹⁷

Dermoscopic algorithms and scoring systems provide a structured framework for evaluating pigmented skin lesions, enhancing the accuracy and reproducibility of dermoscopic interpretations. These tools aid clinicians in making informed diagnostic decisions by systematically assessing key features and assigning scores based on the degree of abnormality. This structured approach not only improves diagnostic accuracy but also facilitates communication and collaboration among healthcare professionals. The two-step algorithm is a widely used method for evaluating pigmented skin lesions under dermoscopy. It involves a systematic assessment of the lesion's global and local features to categorize it as either melanocytic or non-melanocytic. This algorithm helps clinicians narrow down the diagnostic possibilities and focus on the most relevant dermoscopic features. In the first step, the clinician assesses the overall pattern of the lesion, considering features such as distribution of pigment, presence of a pigment network, presence of other patterns. Based on the global pattern, the lesion is categorized as either melanocytic or non-melanocytic. Melanocytic lesions typically exhibit a pigment network, while non-melanocytic lesions do not. This initial categorization helps guide the clinician towards a more specific diagnosis. In the second step, the clinician focuses on specific local features within the lesion, such as dots, globules, streaks, circles. The presence and distribution of these local features help further refine

the diagnosis and differentiate between benign and malignant melanocytic lesions. For example, the presence of irregular dots and globules, especially in a disorganized pattern, may raise suspicion for melanoma. The ABCD rule is a mnemonic device that helps clinicians remember the key dermoscopic features associated with melanoma. The lesion is divided into two halves and assessed for symmetry. Asymmetrical lesions are more suspicious for melanoma, as they reflect the disordered growth pattern of melanoma cells. The border of the lesion is assessed for irregularity. Irregular, notched, or blurred borders are more suspicious for melanoma, as they indicate the invasive nature of the tumor. The lesion is assessed for the presence of multiple colors. Lesions with more than one color are more suspicious for melanoma, as they reflect the presence of different types of melanin and changes in blood flow within the tumor. The diameter of the lesion is measured. Lesions larger than 6 mm are more suspicious for melanoma, although smaller melanomas can occur. While size alone is not a definitive diagnostic criterion, larger lesions warrant closer scrutiny. Each of the ABCD criteria is scored based on its degree of abnormality, with higher scores indicating a greater likelihood of malignancy. The total score is then used to prioritize lesions for further investigation, such as biopsy and histopathological examination. This scoring system helps ensure that suspicious lesions are not overlooked and facilitates timely intervention. In addition to the two-step algorithm and the ABCD rule, several other dermoscopic algorithms and scoring systems have been developed to aid in the evaluation of pigmented skin lesions. The Menzies method uses a point-based system to assess specific dermoscopic features, with higher scores indicating a greater likelihood of melanoma. The 7-point checklist assesses seven specific dermoscopic features, with the presence of two or more features suggesting melanoma. The CASH algorithm categorizes lesions based on the presence of specific dermoscopic features, such as Color, Architecture, Symmetry, and Homogeneity. These algorithms and scoring systems

offer varying levels of complexity and diagnostic accuracy. The choice of which tool to use depends on the clinician's experience, the specific clinical scenario, and the availability of resources. By providing a structured approach to dermoscopic interpretation, these tools help improve the accuracy of melanoma diagnosis. Studies have shown that the use of dermoscopic algorithms and scoring systems can significantly increase the sensitivity and specificity of melanoma detection compared to clinical examination alone. The use of standardized criteria and scoring systems increases the reproducibility of dermoscopic assessments, allowing for more consistent diagnoses among different clinicians. This is particularly important in settings where multiple clinicians are involved in patient care. Scoring systems help clinicians prioritize lesions for further investigation, ensuring that suspicious lesions are not overlooked. This is particularly important in busy clinical settings where time constraints may limit the number of lesions that can be biopsied. Dermoscopic algorithms and scoring systems serve as valuable educational tools, helping clinicians learn and apply the key dermoscopic features associated with melanoma. These tools can be used in training programs and continuing medical education activities to improve clinicians' dermoscopic skills.¹⁸⁻²⁰

4. Conclusion

This case report underscores the crucial role of dermoscopy in the early detection and diagnosis of superficial spreading melanoma in adolescents. The successful treatment and favorable outcome of this case highlight the importance of utilizing dermoscopy in the evaluation of suspicious pigmented lesions in young patients. Dermoscopy, a non-invasive imaging technique, enables detailed visualization of subsurface skin structures, aiding in the differentiation between benign and malignant lesions. The use of dermoscopy in this case allowed for the early identification of melanoma, even though the patient was young and the lesion was located in an area not typically associated with high sun exposure.

This case emphasizes the importance of maintaining a high index of suspicion for melanoma in all age groups and body sites. Clinicians should be vigilant in evaluating pigmented lesions in adolescents and consider dermoscopy as a valuable tool to aid in the diagnostic process. The early diagnosis and prompt treatment of melanoma in this case led to a favorable outcome, with complete tumor eradication and minimal morbidity. This case serves as a reminder of the importance of early detection and intervention in the management of melanoma, particularly in adolescents. Further research is needed to evaluate the effectiveness of dermoscopy in the early diagnosis of melanoma in larger adolescent populations. Educational initiatives aimed at raising awareness about melanoma and the benefits of dermoscopy among clinicians and the public are also essential.

5. References

1. Faldetta C, Kaleci S, Chester J, Ruini C, Ciardo S, Manfredini M, et al. Melanoma clinicopathological groups characterized and compared with dermoscopy and reflectance confocal microscopy. *J Am Acad Dermatol*. 2024; 90(2): 309–18.
2. Pellerone S, Pensa C, Riccio G, Brancaccio G, Argenziano G, Moscarella E. Dermoscopy of thick scalp melanoma: Is it always an easy diagnosis? *Dermatol Pract Concept*. 2024; 14(2): e2024143.
3. De Giorgi V, Silvestri F, Cecchi G, Venturi F, Zuccaro B, Perillo G, et al. Dermoscopy as a tool for identifying potentially metastatic thin melanoma: a clinical-dermoscopic and histopathological case-control study. *Cancers (Basel)*. 2024; 16(7).
4. Ibani A, Aragón-Caqueo D, Naveiro M, Sánchez F, Ríos D, Medina J, et al. Three-Point checklist dermoscopy for melanoma screening: Experience in medical students new to dermatology. *Dermatol Pract Concept* [Internet]. 2024; 14(3): e2024211.
5. Spadafora M, Megna A, Lippolis N, Cavicchi M, Borsari S, Piana S, et al. Dermoscopy and reflectance confocal microscopy of solitary flat pink lesions: a new combined score to diagnose amelanotic melanoma. *J Eur Acad Dermatol Venereol*. 2024.
6. Ibani A, Aragón-Caqueo D, Naveiro M, Sánchez F, Ríos D, Medina J, et al. Three-Point checklist dermoscopy for melanoma screening: Experience in medical students new to dermatology. *Dermatol Pract Concept*. 2024; 14(3): e2024211.
7. Vaccari S, Rossi AN, Roda M, Cassini F, Maltoni L, Dika E. Dermoscopy relevance in eyelid lentigo maligna melanoma. *Dermatol Pract Concept*. 2024; 14(3): e2024157.
8. John-Otumu A, Ekemonye R, Ewunonu T, Aniugo V, Okonkwo O. Optimizing CNN kernel sizes for enhanced melanoma lesion classification in dermoscopy images. *Machine Learning Research*. 2024; 9(2): 26–38.
9. Kameda E, Matsuzawa T, Togawa Y, Hashimoto R, Saito T, Suzuki T, et al. Amelanotic melanoma in oculocutaneous albinism type 4 detected using violet-light dermoscopy. *J Dermatol*. 2024; 51(8): e261–3.
10. Iyatomi H, Oka H, Saito M, Miyake A, Kimoto M, Yamagami J, et al. Quantitative assessment of tumour extraction from dermoscopy images and evaluation of computer-based extraction methods for an automatic melanoma diagnostic system. *Melanoma Res*. 2006; 16(2): 183–90.
11. Cuellar F, Kolm I, Badenas C, Puig-Butille J, Marti Laborda R, Zaballos P, et al. Dermoscopy features of melanoma associated with MC1R gene polymorphism in CDKNA2 mutation Spanish carriers. *Melanoma Res*. 2006; 16(Suppl 1): S21–2.
12. Glud M, Gniadecki R, Drzewiecki KT. Spectrophotometric intracutaneous analysis versus dermoscopy for the diagnosis of pigmented skin lesions: prospective, double-

- blind study in a secondary reference centre. *Melanoma Res.* 2009; 19(3): 176–9.
13. Rubegni P, Cevenini G, Sbrano P, Burrioni M, Zalaudek I, Risulo M, et al. Evaluation of cutaneous melanoma thickness by digital dermoscopy analysis: a retrospective study. *Melanoma Res.* 2010; 20(3): 212–7.
 14. Ponti G, Ruini C, Massi D, Pellacani G, Tomasi A, Paglierani M, et al. Fluorescence in-situ hybridization and dermoscopy in the assessment of controversial melanocytic tumors. *Melanoma Res.* 2013; 23(6): 474–80.
 15. Wu X, Marchetti MA, Marghoob AA. Dermoscopy: Not just for dermatologists. *Melanoma Manag.* 2015; 2(1): 63–73.
 16. Argenziano G. An interview with Giuseppe Argenziano: an insight into the field of dermoscopy. *Melanoma Manag.* 2017; 4(1): 9–11.
 17. Gupta P, Vinay K, Bishnoi A, Kumaran MS, Parsad D. A prospective observational study to sequentially determine the dermoscopic features of vitiligo and its association with disease activity in patients on medical treatment: Dermoscopy and disease activity in vitiligo. *Pigment Cell Melanoma Res.* 2023; 36(1): 33–41.
 18. Zakria D, Brownstone N, Han J, Owji S, Dirr M, Rigel D. Electrical impedance spectroscopy significantly enhances correct biopsy choice for pigmented skin lesions beyond clinical evaluation and dermoscopy. *Melanoma Res.* 2023; 33(1): 80–3.
 19. Janssen L, Van Kelst S, De Smedt J, Terrasson J, Diricx B, Kimpe T, et al. Preoperative assessment of cutaneous melanoma thickness by multispectral dermoscopy. *Melanoma Res.* 2023; 33(1): 84–6.
 20. Liu H, Jiang H, Shan Q. Reflectance confocal microscopy versus dermoscopy for the diagnosis of cutaneous melanoma: a head-to-head comparative meta-analysis. *Melanoma Res.* 2024; 34(4): 355–65.